

Imaging and clinical approaches in the management of patients with spinal cord injury without radiographic abnormality (SCIWORA)

Nikolaos Siatos¹, Ioannis S. Benetos^{1,2}, Dimitrios-Sergios Evangelopoulos^{1,2}, John Vlamis^{1,2}, Maria-Eleftheria Evangelopoulos^{1,3}

¹Postgraduate Training Program, KAT Hospital, National and Kapodistrian University of Athens School of Medicine, KAT Hospital, 2 Nikis str, 14561, Athens, Greece

²3rd Department of Orthopaedic Surgery, National and Kapodistrian University of Athens School of Medicine, KAT Hospital, 2 Nikis str, 14561, Athens, Greece

³1st Department of Neurology, National and Kapodistrian University of Athens School of Medicine, Eginition Hospital, 72-74 Vas. Sofias Av., 11528, Athens, Greece

Abstract

SCIWORA is a syndrome that defines posttraumatic SCI in patients with abnormal clinical neurological examination and apparently normal radiological findings in plain X-rays and CT. Under the suspicion of SCIWORA, early MRI is recommended for definitive diagnosis while prompt neuroprotective measures have to be taken to prevent secondary SCI that may cause further neurological deterioration.

Introduction. SCIWORA (Spinal Cord Injury Without Radiographic Abnormalities) is a syndrome that defines posttraumatic SCI in patients with abnormal clinical neurological examination and apparently normal radiological findings in plain X-rays and CT. This syndrome most commonly affects children, but can be also found in adults, with a predilection for the cervical spine. The aim of this study is to review the imaging and clinical approaches in the management of SCIWORA patients.

Materials & Methods. A literature review was conducted based on the Pubmed internet database, following the PRISMA Guidelines. Article titles were searched with the use of the keywords: "Spinal Cord Injury without Radiographic Abnormality" OR "SCIWORA". The search included only clinical studies evaluating SCIWORA in adults. Studies published in non-English language, animal studies, experimental studies, case reports, reviews, and commentary studies were excluded. Moreover, studies in children and adolescents were also excluded.

Results. Initially, 207 studies were identified after primary search on Pubmed electronic database. After screening of titles and abstracts, 15 articles were excluded. Among the remaining 192 studies, 167 were rejected for various reasons (figure 1). After checking the references lists of the included studies, 2 more studies were added, leaving 29 studies for final analysis. The total number of patients was 1418 (78.2%

Corresponding
Author

Dimitrios-Sergios Evangelopoulos,
ds.evangelopoulos@gmail.com

men) with a mean age of 53.5 years. The incidence of SCIWORA among all SCI cases varies from 1.3 – 12%. The most common cause of SCIWORA is fall from a height (53%), followed by motor vehicle accidents (33.6%), sports injuries (6.4%), occupational injuries (2.8%) and other injuries (4.6%). 94.4% of the SCIWORA occurred in the cervical spine, while the rest 5.2% occurred in the thoracic spine. The most common mechanism of injury is hyperflexion of the cervical spine especially in patients with preexisting cervical spondylosis. 12% of patients were AIS grade A, 20% AIS grade B, 35% AIS grade C and 33% AIS grade D. In 14.2% of patients, no MRI abnormalities were detected, while 85.8% of patients had abnormal MRI scan results. Among them, 57.0% had extraneural, 36.3% had intraneural and 6.6% of patients had combined extraneural and intraneural MRI abnormalities. Initial treatment is conservative. Indications for surgical management include MRI findings of cord compression and instability, along with deterioration of neurological symptoms. Prognosis of SCIWORA depends on the initial neurological deficit and magnitude of SCI on MRI; however, neurological improvement is expected in at least 75% of patients.

Conclusions. SCIWORA is an underestimated clinical condition in adult SCI patients. In the suspicion of SCIWORA, early MRI is recommended for definitive diagnosis and prompt neuroprotective measures have to be taken to prevent secondary SCI that may cause further neurological deterioration for a better prognosis. According to MRI findings, surgical treatment is indicated in patients with cord compression and instability and worsening neurological symptoms. More high quality studies are needed to fully elucidate the optimal imaging and clinical approaches in the management of SCIWORA patients.

Keywords: Spinal cord injury; SCIWORA.

Introduction

Spinal cord injury (SCI) is one of the most challenging medical conditions, strongly associated with high mortality rates, ongoing disability, significant deterioration of quality of life and a severe socio-economic burden to the patients and the society. SCI is usually caused by spinal trauma, usually due to motor vehicle accidents, falls, occupational injuries, gunshot or stabbing wounds. Non-traumatic SCIs may be caused by infections, tumors or degenerative conditions [1]. The degree of disability caused by the SCI depends on the site and the extent of the injury. Diagnosis is based on clinical and imaging findings, especially X-rays, computed tomography (CT) and magnetic resonance imaging (MRI), which may reveal spinal fractures, dislocations, spinal cord edema and hemorrhage. However, there are cases, especially in children, where the spinal cord is injured without any evident imaging findings.

Spinal cord injury without radiographic findings, also known as SCIWORA (Spinal Cord Injury Without Radiographic Abnormalities-SCIWORA) syndrome, was first described by Pang et al, as a

SCI in a child without radiologic abnormalities on plain x-ray film [2]. SCIWORA is a known entity in populations of children sustaining a cervical spine injury [2], but its incidence in adults varies considerably between different studies. In 1948, Barnes et al reported the first case series of five adults experiencing SCI presenting with a clinicoradiologic mismatch [3]. The concept of SCIWORA was extended to adult practice by Hirsh et al, who adopted the term to report the case of an adult with a thoracic SCI with apparently normal X-rays [4]. Thereafter, further reports provided more data to the existence of SCIWORA in adults. However, taking into consideration the differences in spinal anatomy, direct comparisons between children and adults with SCIWORA have usually been avoided [5, 6].

By definition, SCIWORA originally assumed negative radiographs only. With the evolution of more advanced imaging techniques, the absence of pathologic findings on CT was incorporated in the diagnostic criteria of SCIWORA. Subsequently some argued that the following terms should be used for adult patients: “Spinal Cord Injury Without Radio-

logical Evidence of Trauma" (SCIWORET) or "Spinal Cord Injury Without CT Evidence of Trauma" (SCIWOCTET), so as to exclude cases where plain radiographs and CT are normal, but cervical spondylosis is present [7, 8]. The introduction of CT and the imaging of very small lesions that may conceal hidden injuries have reportedly led to a reduction in the incidence of SCIWORET in adults from 14% to 5% [9, 10].

The increasing availability of MRI added another diagnostic examination for the identification of intraneural and extraneural abnormalities in patients experiencing SCI. However, the role of MRI in the diagnosis, prognosis, and management of SCIWORA patients has not been fully elucidated. There are rare cases of SCIWORA, where even MRI can be normal. These cases have been evaluated under the definition of "real SCIWORA" [11]. Furthermore, the lack of a reliable classification system based on the morphologic MRI abnormalities weakens the interpretability and comparability of relevant studies. Some authors referring to SCIWORA syndrome, have also included in their studies patients with an increased prevertebral intensity or a fracture in the anterior-superior angle of the vertebral body [12, 13], which, however, are well documented points suggestive of trauma, thus creating further confusion in the literature. In 2005, there has been a recommendation that the term SCIWORA in adults should also include negative MRI in addition to negative x-rays and CT [14]. However, typically, the radiological examination does not involve MRI and therefore it should not be considered a prerequisite for the definition of the syndrome [15].

The aim of this study was to review the imaging and clinical approaches in the management of patients with Spinal Cord Injury without Radiographic Abnormality (SCIWORA).

Materials And Methods

A literature review was conducted based on the online Pubmed database, following the PRISMA Guidelines, with the use of the EndNote X3 software (Thompson Reuters) [16]. Article titles were searched with the use of the keywords: "Spinal Cord Injury without Radiographic Abnormality" OR "SCIWO-

RA". The search included only clinical studies evaluating SCIWORA in adults. Studies published in non-English language, animal studies, experimental studies, case reports, reviews, and commentary studies were excluded. Moreover, studies in children and adolescents were also excluded.

Results

Initially, 207 studies were identified after primary search on the online Pubmed database. After screening of titles and abstracts, 15 articles were excluded. From the remaining 192 studies, 165 were rejected for various reasons (figure 1). After checking the references lists of the included studies, 2 more studies were added, leaving 29 studies for final analysis.

The 29 selected studies were published from 1999 to 2022. Table 1 depicts all the included studies in the present review. The total number of patients was 1418 (78.2% men) with a mean age of 53.5 years.

Incidence

According to the included studies in this review, the incidence of SCIWORA varied from 1.3% to 12% [5, 6, 15, 18, 20, 25]. The incidence of SCIWORA in the large NEXUS (National Emergency X-Radiography Utilization Study) study was 3%, but the authors stated that this low rate could be underestimated [22].

Mechanism of injury

Road traffic accidents and falls were the two most common causes of SCIWORA. According to the present review, the most common cause of SCIWORA was fall from a height (53%), followed by motor vehicle accidents (33.6%), sports injuries (6.4%), occupational injuries (2.8%) and other injuries (4.6%).

Site of injury

The most common site of SCIWORA was the cervical spine. According to the present review, 94.4% of the SCIWORA occurred in the cervical spine, while the rest 5.2% occurred in the thoracic spine. These findings come in agreement with the literature, as the thorax and abdomen protect the thoracic spine from excessive flexion or extension, providing inherent stability [42]. According to the epidemiological study by Guo et al, the C4 - C5 segment was the

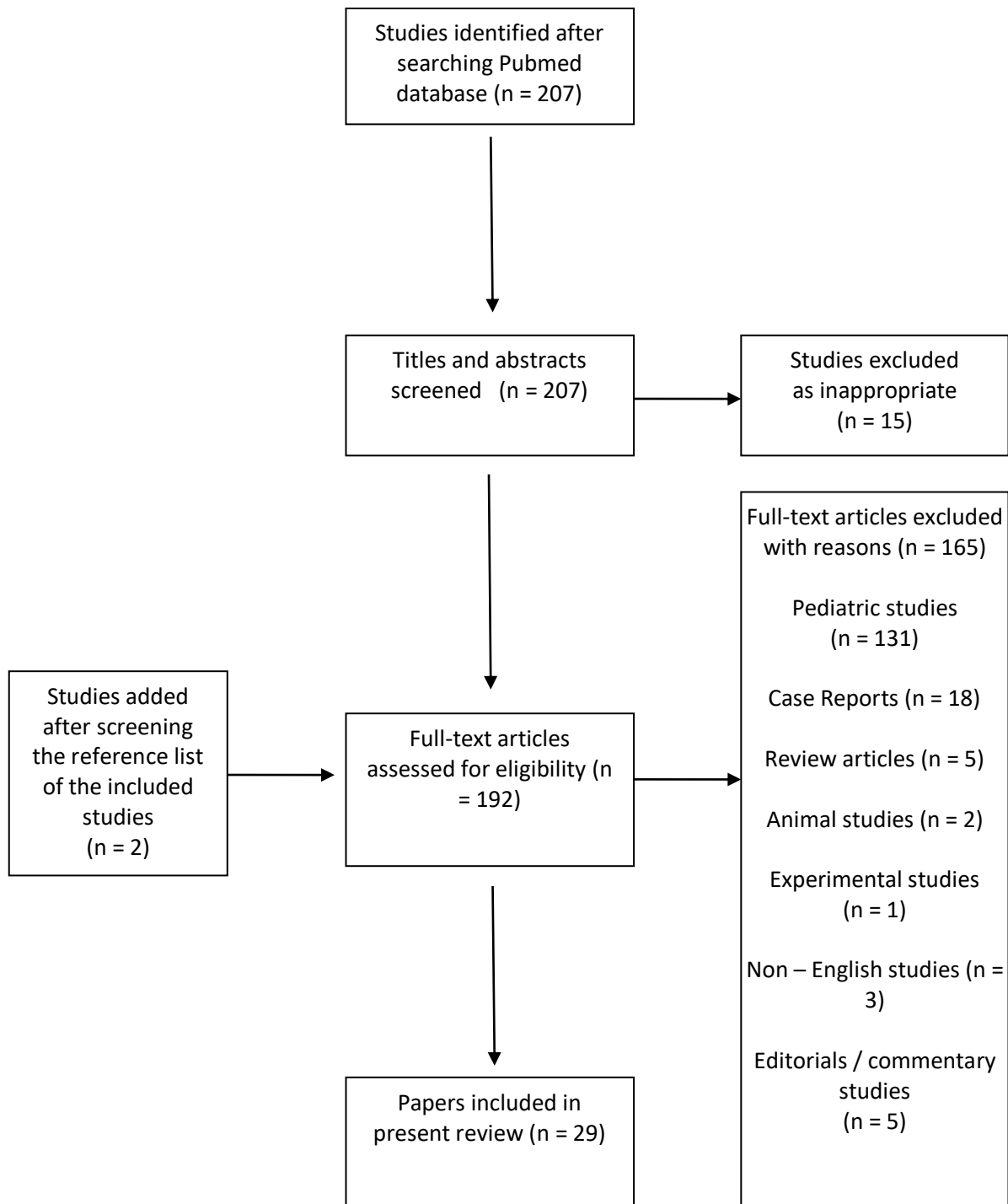


Figure 1. Study flowchart

most commonly affected level (48.7%) followed by C5 - C6 and C3 - C4 (30.5 and 12.8%, respectively) [21].

Pathophysiology

Guo et al, in the largest included case series, analyzed 203 cases of SCIWORA and concluded that combined hyperextension, flexion, and distraction of the head is the most frequent mechanism [21]. In most adult patients, SCIWORA are the result of hyperextension injury to the spine, as a result of rear end motor vehicle collisions or direct anterior craniofacial trauma [35]. In older patients, a syndrome of SCI without obvious skeletal injury was reported by the studies of Crooks, Birkett, Schneider et al [43, 44]. Many of these patients have pre-existing cervical spondylosis resulting in narrowing of the cervical canal and predisposing to SCI even after minor trauma [18]. Hyperextension injuries in these patients cause the spinal cord to be compressed between the posterior vertebral osteophytes and the inward bulging of the ligamentum flavum resulting in an acute central cord syndrome [15]. Moreover, a direct blow to the spine could produce shock-wave oscillations causing 'slapping damage' to the spinal cord against the bony spinal canal [45]. In case of hyperextension injuries, the upper extremities are more affected than the lower extremities and most patients have incomplete SCI, with a good prognosis [44].

Risk factors

The calculated mean age of patients in the present review is 53.5 years. 78.2% of patients with SCIWORA were men. Age is an important consideration when evaluating patients with SCIWORA, as the syndrome is very rarely seen between the ages of 16-35. Children under 8 years of age and adults over 60 are the patients who mostly experience it, but these two populations have different characteristics. As far as children are concerned, the relatively large size of the head together with the increased intrinsic mobility of the developing skeleton, as well as the concomitant ligamentous laxity, make spinal cord vulnerable to high energy damage. On the other hand, the elderly patient population has almost unique characteristics: these patients often

have posterior osteophytes and marginal bulging of the ligamentum flavum due to loss of intervertebral disc height, and are thus susceptible to developing central cord syndrome after a hyperextension injury of the cervical spine, as can happen after a fall from the same height.

Clinical Findings

SCIWORA patients may present with a variety of neurological signs, such as tetraplegia, motor and sensory dysfunction, and loss of bladder and bowel function, in addition to local pain, range of motion limitation, edema and bruising around the vertebral column. For the clinical evaluation of the SCIWORA patients, 3 clinical scales were used: the American Spinal Injury Association (ASIA) Impairment Scale (AIS), the Frankel scale and the Japanese Orthopedic Association (JOA) score [46, 47]. Fourteen of the included studies used the AIS scale. 12% of patients were AIS grade A, 20% AIS grade B, 35% AIS grade C and 33% AIS grade D. Six studies used the Frankel scale. The largest study of Guo et al included 66 AIS A patients, 77 AIS B, 36 AIS C and 24 AIS D [21].

Imaging findings

The timely and accurate diagnosis of SCI is of paramount importance in order to initiate appropriate therapeutic intervention [48]. X-rays along with CT are vital for the proper identification of the site and the severity of the injury [49]. Note that by definition, SCIWORA consists of a negative radiological screening (plain x-rays and CT), but not a negative MRI. Invasive imaging methods such as myelography have a limited use [50]. Dynamic imaging in SCIWORA patients following negative plain X-rays and CT images does not provide any diagnostic advantage [51].

Spinal MRI provides valuable additional data for the status of the spinal cord and spinal nerves [52, 53]. The rate of abnormal MRI findings after a normal CT result is 15%, but the majority of these findings had no clinical significance, and in only 0.3% of cases the additional information provided by the MRI led to a surgical intervention [52]. Taking these into consideration, abnormal findings on MRI may lead to overestimation of SCI, in comparison to intraoperative

Table 1. Case series included in the present review. N = Number of patients. NM: Non - mentioned				
AUTHOR	YEAR	N	MEAN AGE (years)	% MALE
Asan ^[17]	2018	11	55	36,4
Boese ^[18]	2013	21	35,5	57,1
Boese ^[19]	2016	26	52	65,4
Cao ^[20]	2022	164	56,3	74,4
Guo ^[21]	2011	203	55,9	88,2
Gupta ^[5]	1999	15	38,8	80,0
Hendey ^[22]	2001	27	42	81,5
Huang ^[23]	2013	5	48,8	80,0
Kasimatis ^[15]	2008	7	66,8	100,0
Kawano ^[24]	2012	54	62,4	81,5
Kothari ^[12]	2000	4	31	75,0
Liu ^[25]	2015	59	41,1	69,5
Machino ^[26]	2011	100	55	79,0
Machino ^[27]	2019	100	55	79,0
Maeda ^[28]	2012	88	64	89,8
Martinez-Perez ^[29]	2017	49	54	81,6
Na ^[30]	2021	11	63,8	100,0
Neva ^[31]	2011	32	46,9	90,6
Ouchida ^[32]	2016	68	62	76,5
Qi ^[33]	2020	57	49,2	77,2
Qi ^[34]	2022	106	50,5	NM
Sharma ^[35]	2009	12	38,7	83,3
Shen ^[36]	2006	5	27,8	60,0
Tan ^[37]	2022	86	51,7	57,0
Tewari ^[6]	2005	40	42,1	77,5
Wang ^[38]	2015	52	NM	NM
Yaqoob Hakim ^[39]	2021	11	46,5	90,9
Zhang ^[40]	2015	16	46,5	75,0
Zhu ^[41]	2019	16	47,5	81,3

Table 2. Classification of SCIWORA in adults by MRI imaging type [57].

MRI Imaging Type	MRI abnormalities
I	No detectable abnormalities
Ila	Extraneural abnormalities
Ilb	Intraneural abnormalities
Ilc	Extraneural + Intraneural abnormalities

Table 3. Classification of intramedullary abnormalities in adults by MRI imaging type [63].

Pattern	Cord Finding	MRI imaging
I	Hemorrhage	Large central area of hypointensity surrounded by a thin rim of hyperintensity on T2W images
II	Edema	Area of hyperintensity on T2W images
III	Contusion	Thin area of central hypointensity and thick rim of hyperintensity on T2W images

findings [54]. However, as a few SCIs may require immediate surgical management, MRI within 24 hours of injury has been recommended in patients, with clinical SCI findings and normal X-rays and CT [18]. In case of a normal early MRI, a second MRI in 72 hours post injury may reveal spinal cord changes [55, 56]. After all, MRI has been the gold standard in the diagnostic approach of suspected SCI patients.

MRI has the capacity to detect characteristic pathomorphological extraneural and intraneural abnormalities. Intraneural abnormalities include spinal cord edema, bleeding, contusion and transection (partial or complete). Extraneural findings concern lesions to the soft tissues surrounding the spinal canal including intervertebral disc herniation, ligamentum flavum folding, prevertebral soft tissue edema, or ligamentous abnormalities [57, 58]. Epidural hematomas are very rarely reported, especially in patients with ankylosing spondylitis or severe cervical spondylosis [59].

Boese et al described a classification system of SCIWORA based on MRI findings, where type I was defined as a normal MRI scan, while type II includes three abnormal subtypes (Table 2) [57]. The present review included 1175 adult SCIWORA patients with reported MRI findings. In 167 patients (14.2%), no MRI abnormalities were detected (Type I), while

1008 (85.8%) had abnormal MRI scan results (Type II). Of these, 575 patients (57.0%) had extraneural (Type Ila); 366 patients (36.3%) had intraneural (Type Ilb); and 67 patients (6.6%) had combined extra and intraneural MRI abnormalities (Type Ilc).

An intervertebral space abnormality is indicative of a possible damage of the intervertebral disc that can be clearly visualized by MRI as a disruption or herniation. In case of a disruption, the disc injury is best seen on sagittal T2WI as high signal intensity in the intervertebral space and low signal intensity on sagittal T1WI [60]. Disc abnormalities after injury are reported to range from 16% to 48% in patients with SCIWORA [22, 61, 62] and Tewari et al noted a 37.5% rate of disc herniation [6].

The anterior longitudinal ligament (ALL) is a crucial component of the anterior spinal column. ALL injury causes bleeding and edema in the prevertebral space, including ALL, the prevertebral muscle and the intervertebral disk. This change is visualized as high-signal intensity on T2W1 MR imaging. This prevertebral hyperintensity (PVH) suggests a hyperextension mechanism of the injury [32]. The rate of PVH in SCIWORA has been estimated at 76% to 90% [26-28, 32].

The posterior longitudinal ligament (PLL) is a

component of the posterior spinal column connecting the posterior surfaces of the vertebral bodies. It weakly prevents hyperflexion of the vertebral column. The cervical PLL is comparatively narrow and thin, and strongly adherent to the posterior annulus fibrosus. In patients with non-traumatic disc herniation, nucleus pulposus may break through the PLL and posterior annulus fibrosus. According to the large case series by Guo et al, PLL rupture is the most common type of injury in SCIWORA patients, accounting for 43.8%, followed by ALL rupture in 25.1% [21].

Significant changes in signal intensity of the spinal cord, because of hemorrhage, contusion, or edema, are best seen in T2WI. Increased high-signal intensity (ISI) is a finding, often seen in SCIWORA patients. According to the study by Kulkarni et al, published in 1988, there are 3 imaging patterns of intramedullary spinal cord abnormalities (cord haemorrhage, oedema and mixed type) (Table 3) [63], and their prognostic value has been the focus of a number of reports [52, 64]. The rate of ISI in SCIWORA has been estimated at 92% to 94%, according to the studies by Machino et al and Ouchida et al [26, 27, 32].

In contrast to the pediatric patient population, negative MRI in adult patients with SCIWORA is questionable. One could argue that the strength of the magnetic field or the acquisition technique is responsible for not imaging small intramedullary signal changes. In general, the disclosure of technical information on image acquisition was insufficient, although selection and interpretation of the appropriate imaging technique are critical for the diagnosis of SCIWORA in adults [65]. Various scanning methods are available, and novel approaches may provide additional information, particularly regarding intramedullary signal changes. In fact, a study by Shen et al reported that Diffusion-weighted MRI (DWI) can be used as a method to assess the spinal cord integrity [36]. Patients with absence of intramedullary signal changes on conventional MRI presented high-intensity signals on DWI. It is therefore possible that this technique will help to further investigate patients with SCIWORA who are considered to have a negative MRI.

Prognosis

According to this review, 75% of the SCIWORA patients were reported to exhibit neurological improvement. Prognosis of SCIWORA patients depends on neurological status and MRI findings. The association between the severity of initial neurologic impairment and subsequent improvement is similar to the outcome characteristics of SCIs with radiologic abnormalities [66]. According to Neva et al, in-hospital mortality of all SCIWORA patients was 0.9%, increasing to 3.7% in patients with complete tetraplegia or paraplegia (ASIA A) [67]. In contrast, ASIA B to D patients were associated with a significantly better overall survival (mortality rate 0.2%). Martinez-Perez et al observed that, at one-year after SCIWORA, complete neurological recovery was achieved only in patients with incomplete neurological injury at admission [29]. Most SCIWORA adult patients were unable to return to work; however, the extent of the entire socioeconomic impact has to be clarified [31]. Maeda et al confirmed that prognosis of SCIWORA patients was mainly related to the injury mechanism, the spinal canal diameter, patient age, the injury degree, the presence of disk-ligament injury and the severity of the neurological syndrome [28]. In contrast, according to a recent study by Cao et al, the prognosis is not affected by preoperative neurologic status, age, gender, comorbidities and cause of injury [20].

Although it has been suggested that MRI findings are important prognostic indicators in SCIWORA patients [5, 21, 68], this scenario has not yet been fully clarified. A systematic review published in 2008 showed an association between radiological findings and clinical improvement and observed a more favorable prognosis in patients without cord injury in MRI [69]. In 2016, Boeze et al reported an association between imaging type and neurological outcome in adult SCIWORA patients, presenting a superior prognosis of patients with no detectable neuroimaging abnormalities over patients presenting with type II lesions. Moreover, patients with combined extraneural and intraneural abnormalities had a higher risk of persistent neurological impairment in comparison to those with isolated ex-

traneural abnormalities, followed by patients with intraneural abnormalities [19].

On the contrary, Boese et al found that the absence of MRI abnormalities was not predictive of a good outcome. According to their study, spinal cord edema was correlated with only partial cord symptoms and patients experienced complete motor and sensory remission within 24 hours. 37.5% of patients without spinal cord damage on MRI and 40% of patients with isolated soft tissue bulging into the spinal canal showed incomplete recovery [18]. Asan et al observed 4 patients without SCI on MRI, who did not have a favorable course [17]. Moreover, there was no significant correlation between the severities of the clinical findings, the clinical progression and the MRI cord abnormalities [17].

In addition, MRI provides valuable information on intramedullary signal changes and their longitudinal extension, which are well-documented prognostic factors after SCI. The outcome is worst in patients with cord disruption, poor in patients with cord haemorrhage and good in patients with cord oedema or normal cord [41]. Edema of the spinal cord obviously has the best prognosis, while the presence of hemorrhage makes the outcome less good, especially if it occupies more than 50% of the transverse diameter of the spinal cord [6]. Occupancy ratio and spinal cord high signal changes in MRI T2WI were associated with poor prognosis, according to Cao et al [20]. Grabb and Pang reported a definite association between abnormal MRI findings and the severity of neurological impairment, and they presented their classification to prognosticate SCIWORA based on MRI findings [68]: (1) worse if there is intramedullary hematoma occupying more than 50% of the cross-sectional area of the spinal cord, (2) intermediate if the contusions are minor and associated with edema, (3) better in patients where there is cord edema, and (4) the best when there are no changes in the spinal cord. After edema subsides, improvement can be seen in patients [68, 70]. According to Na et al, intramedullary lesion length on T2 images and spinal cord compression rate on T1 images had the most powerful effect on neurological improvement [30]. Neva et al suggested that more severe maximum spinal cord compression

correlated well with worse Frankel grade [31]. It is also reported that the extension of the pathologic signal to multiple levels has a poor prognosis [71]. In 2006, Boldin et al quantified this parameter, defining that a hemorrhagic lesion ≤ 4 mm in length is an important factor for incomplete SCI damage and better prognosis [72]. Consequently patients with extensive intramedullary lesions, particularly with bleeding areas, should be expected to have a poor outcome.

According to Machino et al, the presence of ISI may be associated with the preoperative neurologic status of the patient. The range of ISI was larger in severely paralyzed cases. Increased ISI is associated with symptom severity and neurological prognosis [26]. Ouchida et al found that, when comparing acute and delayed MRI results, there were significant differences in the prevalence rates of ISI. Delayed MRI findings provide more accurate information about symptom severity in comparison with acute findings, giving useful information about the state of the spinal cord [32].

Extraneural findings are generally less severe than intraneural findings. According to Boese et al, intraneural MRI abnormalities (type II) were associated with an inferior outcome when compared with patients without intraneural abnormalities. The combination of extraneural and intraneural lesions (Type IIc) was associated with a high risk of poor neurological outcome [19]. According to the study by Gupta et al, the best neurological recovery occurred in patients with disc herniation. This is not surprising as these patients had no spinal cord damage and surgical removal of the herniated disk resulted in neurological recovery. In these patients, MRI therefore has a definite prognostic value [5].

According to Martinez-Perez et al, disruption of either the ALL or the ligamentum flavum and larger lesions in the MRI have been noted as predictors of lack of neurological improvement. Shorter lesions and integrity of the ligamentum flavum were significantly associated with neurological improvement [29]. According to Machino et al, the presence of PVH may indeed be associated with the preoperative neurologic status of the patient. The range of PVH was larger in severely paralyzed cases [26]. Ouchida

et al found that, when comparing acute and delayed MRI results, there were significant differences in the prevalence rates of PVH [32]. Maeda et al concluded that the area of PVH had a significant negative correlation with the ASIA motor score, indicating that patients who had larger PVH tended to show severe paralysis. All these findings suggest that the soft-tissue injury at the time of trauma strongly affects the patients' neurological status [28].

Cervical ossification of the PLL is another risk factor for SCIWORA. The prevalence of cervical ossification of the PLL among SCI patients was higher than the general prevalence rate. Two possible mechanisms have been proposed. At the time of traumatic injury, the spinal cord under static compression of ossified PLL could be abruptly pinched by ossification mass, resulting in secondary SCI. Moreover, patients with ossified PLL have a narrow cerebrospinal fluid zone, resulting in a decrease of the buffering and protective potential of cerebrospinal fluid. In traumatic injuries, the traumatic force will be directly conducted to the spinal cord, which may induce a concussion of the spinal cord [20]. Cao et al stated that when patients with cervical ossification of the PLL had traumatic injury, cervical SCI without effective protective potential of cerebrospinal fluid may lead to a poor prognosis [20].

Treatment

Prompt management of SCIWORA is mostly empirical and is not based on randomized controlled trials. Initial treatment of SCIWORA is conservative and includes immobilization and corticosteroid therapy. Immobilization is initiated immediately after the injury, and includes hard collars, cervical or cervical-thoracic braces or thoracolumbar orthosis, for at least 3 months. All SCIWORA patients should abstain from any physical activity for at least 6 months. Immobilization of the spine continues until clinical examination becomes normal, and no instability is evident on MRI. IV steroid therapy is routinely administered, within 8 hours after injury, before the implementation of MRI, for the prevention of secondary injury [51]. Asan et al administered only methylprednisone to the 11 patients of their study [17].

Surgical management of SCIWORA patients is

indicated in cases of clear MRI evidence of persistent ligamentous instability and cord compression, along with worsening neurological symptoms or lack of improvement [51]. Anterior cervical decompression with fusion (ACDF) is the main surgical method for surgical management of adult cervical SCIWORA, which can relieve the symptoms of cervical spinal cord compression promoting the recovery of cervical spinal cord function [20, 33]. Posterior surgery is recommended only in cases of severe total cervical spinal stenosis. Surgical decompression of the spinal cord can restore topical blood circulation and reduce edema, thus reducing or normalizing the high signal intensity in the intramedullary region. Patients with high signal intensity in the intramedullary region in MRI T2WI can have good prognosis after surgery when they are at early stage of edema and demyelination [20, 37]. In case of surgical management, ACDF with Fidji cervical cage is a safe option for these patients, leading to significant functional improvement [23].

Surgical treatment can significantly improve the prognosis of SCIWORA patients with type IIc abnormalities. In the case series by Boese et al, surgical procedures were performed in cases with mixed extraneural and intraneural lesions. All the other patients were treated conservatively [19]. Wang et al concluded that timing of surgery (less than 3 months) was not significantly associated with neurologic recovery [38]. On the contrary, according to Qi et al, the optimal schedule of surgical treatment was 3–7 days after injury, which can significantly improve the short and long-term follow-up effects. Longer the time to surgery from the time of injury, the worse was the prognosis [33].

Rupture of the ALL is definite evidence of cervical disc injury. Intraoperative disc contrast injection during anterior cervical surgery can detect cervical disc rupture and determine the segment responsible for SCIWORA [40]. In comparison to percutaneous disc injection, intraoperative disc injection avoids the risk of iatrogenic injury during needle puncture. However, intraoperative disc contrast injection may prolong surgical time and is associated with increased X-ray exposure of the patients [40].

According to Martinez-Perez et al, type of treat-

ment (conservative vs surgical) does not have a significant impact on neurological outcome [29]. Na et al stated that adequate surgical decompression may have limited contribution to the recovery of neurological function [30]. Kawano et al observed that surgical management was not beneficial in comparison to conservative treatment, in SCIWORA patients [24]. Mazaki et al treated conservatively the SCIWORA patients with incomplete injury and had a good prognosis [73]. However, long-term follow-up showed that some patients were at enormous risk of secondary injury, with more severe neurological damage and poor prognosis [74]. Therefore, blind conservative treatment is also not recommended.

Conclusions

SCIWORA is a syndrome that defines posttraumatic SCI in patients with abnormal clinical neurological examination and apparently normal radiological findings in plain X-rays and CT. This syndrome most commonly affects children, but can also be found in adults, with a predilection for the cervical spine. In adults, most common causes are falls from height and motor vehicle accidents. The most common mechanism of injury is hyperflexion, of the cervical spine especially in patients with preexisting cervical spondylosis. In the present review, the total number of patients was 1418 (78.2% men) with a mean age of 53.5 years. According to the included studies of this review, the incidence of SCIWORA varies from 1.3% to 12%. 94.4% of the SCIWORA occurred in the cervical spine, while the rest 5.2% occurred in the thoracic spine. Diagnosis of SCIWORA includes histo-

ry and clinical examination, followed by plain X-rays and CT. Taking into consideration that plain radiological examination is normal, MRI is the gold standard in the diagnostic evaluation of these patients, not only for its ability to depict the injured spinal cord, but also its capacity to predict the outcome. In 14.2% of patients, no MRI abnormalities were detected, while 85.8% of patients had abnormal MRI scan results. Among them, 57% had extraneural, 36.3% had intraneural and 6.6% of patients had combined extraneural and intraneural MRI abnormalities. Initial treatment is conservative including immobilization for at least 3 months and steroid administration within 8 hours following injury. Surgical treatment, mostly ACDF, is indicated for patients with clear MRI evidence of spinal cord compression, ligamentous injury and instability, along with worsening neurological condition. However, there are studies which do not find any benefit of the surgical treatment over the conservative management. Prognosis of SCIWORA depends on the initial neurological deficit and magnitude of SCI on MRI; however, neurological improvement is expected in at least 75% of patients. Under the suspicion of SCIWORA, early MRI is recommended for definitive diagnosis while prompt neuroprotective measures have to be taken to prevent secondary SCI that may cause further neurological deterioration. More high-quality studies are needed to fully elucidate the optimal imaging and clinical approaches in the management of SCIWORA patients.

Conflict of interest

The authors declare no conflicts of interest.

References

1. El Masri WS, Kumar N. Traumatic spinal cord injuries. *Lancet*. 2011 Mar 19;377(9770):972-4.
2. Pang D, Wilberger JE, Jr. Spinal cord injury without radiographic abnormalities in children. *J Neurosurg*. 1982 Jul;57(1):114-29.
3. Barnes R. Paraplegia in cervical spine injuries. *J Bone Joint Surg Br*. 1948 May;30B(2):234-44.
4. Hirsh LF, Duarte L, Wolfson EH. Thoracic spinal cord injury without spine fracture in an adult: case report and literature review. *Surg Neurol*. 1993 Jul;40(1):35-8.
5. Gupta SK, Rajeev K, Khosla VK, Sharma BS, Paramjit, Mathuriya SN, et al. Spinal cord injury without radiographic abnormality in adults. *Spinal Cord*. 1999 Oct;37(10):726-9.
6. Tewari MK, Gifti DS, Singh P, Khosla VK, Mathuriya SN, Gupta SK, et al. Diagnosis and prognostication of adult spinal cord injury without radiographic abnormality using magnetic resonance imaging: analysis of 40 patients. *Surg Neurol*. 2005 Mar;63(3):204-9; discussion 9.
7. Tator CH, Duncan EG, Edmonds VE, Lapczak LI, Andrews DF. Changes in epidemiology of acute spinal cord injury from 1947 to 1981. *Surg Neurol*. 1993 Sep;40(3):207-15.
8. Como JJ, Samia H, Nemunaitis GA, Jain V, Anderson JS, Malangoni MA, et al. The misapplication of the term spinal cord injury without radiographic abnormality (SCIWORA) in adults. *J Trauma Acute Care Surg*. 2012 Nov;73(5):1261-6.
9. Tator CH. Spine-spinal cord relationships in spinal cord trauma. *Clin Neurosurg*. 1983;30:479-94.
10. Saruhashi Y, Hukuda S, Katsuura A, Asajima S, Omura K. Clinical outcomes of cervical spinal cord injuries without radiographic evidence of trauma. *Spinal Cord*. 1998 Aug;36(8):567-73.
11. Dreizin D, Kim W, Kim JS, Boscak AR, Bodanapally UK, Munera F, et al. Will the Real SCIWORA Please Stand Up? Exploring Clinicoradiologic Mismatch in Closed Spinal Cord Injuries. *AJR Am J Roentgenol*. 2015 Oct;205(4):853-60.
12. Kothari P, Freeman B, Grevitt M, Kerslake R. Injury to the spinal cord without radiological abnormality (SCIWORA) in adults. *J Bone Joint Surg Br*. 2000 Sep;82(7):1034-7.
13. Bhatoe HS. Cervical spinal cord injury without radiological abnormality in adults. *Neurol India*. 2000 Sep;48(3):243-8.
14. Diaz JJ, Jr., Aulino JM, Collier B, Roman C, May AK, Miller RS, et al. The early work-up for isolated ligamentous injury of the cervical spine: does computed tomography scan have a role? *J Trauma*. 2005 Oct;59(4):897-903; discussion -4.
15. Kasimatis GB, Panagiotopoulos E, Megas P, Matzaroglou C, Gliatis J, Tyllianakis M, et al. The adult spinal cord injury without radiographic abnormalities syndrome: magnetic resonance imaging and clinical findings in adults with spinal cord injuries having normal radiographs and computed tomography studies. *J Trauma*. 2008 Jul;65(1):86-93.
16. Barnett I, Malik N, Kuijjer ML, Mucha PJ, Onnela JP. EndNote: Feature-based classification of networks. *Netw Sci (Camb Univ Press)*. 2019 Sep;7(3):438-44.
17. Asan Z. Spinal Cord Injury without Radiological Abnormality in Adults: Clinical and Radiological Discordance. *World Neurosurg*. 2018 Jun;114:e1147-e51.
18. Boese CK, Nerlich M, Klein SM, Wirries A, Ruchholtz S, Lechler P. Early magnetic resonance imaging in spinal cord injury without radiological abnormality in adults: a retrospective study. *J Trauma Acute Care Surg*. 2013 Mar;74(3):845-8.
19. Boese CK, Müller D, Bröer R, Eysel P, Krischek B, Lehmann HC, et al. Spinal cord injury without radiographic abnormality (SCIWORA) in adults: MRI type predicts early neurologic outcome. *Spinal Cord*. 2016 Oct;54(10):878-83.
20. Cao B, Li F, Tang Y, Jia L, Chen X. Risk Factors for Poor Prognosis of Spinal Cord Injury without Radiographic Abnormality Associated with Cervical Ossification of the Posterior Longitudinal Ligament. *Biomed Res Int*. 2022;2022:1572341.
21. Guo H, Liu J, Qi X, Ning G, Zhang H, Li X, et al. Epidemiological characteristics of adult SCIWORA in Tianjin, China: a preliminary study. *Eur Spine J*. 2012 Jan;21(1):165-71.
22. Hendey GW, Wolfson AB, Mower WR, Hoffman JR.

- Spinal cord injury without radiographic abnormality: results of the National Emergency X-Radiography Utilization Study in blunt cervical trauma. *J Trauma*. 2002 Jul;53(1):1-4.
23. Huang SL, Yan HW, Wang KZ. Use of Fidji cervical cage in the treatment of cervical spinal cord injury without radiographic abnormality. *Biomed Res Int*. 2013;2013:810172.
 24. Kawano O, Ueta T, Shiba K, Iwamoto Y. Outcome of decompression surgery for cervical spinal cord injury without bone and disc injury in patients with spinal cord compression: a multicenter prospective study. *Spinal Cord*. 2010 Jul;48(7):548-53.
 25. Liu Q, Zhao J, Yu H, Ma X, Wang L. Early MRI finding in adult spinal cord injury without radiologic abnormalities does not correlate with the neurological outcome: a retrospective study. *Spinal Cord*. 2015 Oct;53(10):750-3.
 26. Machino M, Yukawa Y, Ito K, Nakashima H, Kanbara S, Morita D, et al. Can magnetic resonance imaging reflect the prognosis in patients of cervical spinal cord injury without radiographic abnormality? *Spine (Phila Pa 1976)*. 2011 Nov 15;36(24):E1568-72.
 27. Machino M, Ando K, Kobayashi K, Ota K, Morozumi M, Tanaka S, et al. MR T2 image classification in adult patients of cervical spinal cord injury without radiographic abnormality: A predictor of surgical outcome. *Clin Neurol Neurosurg*. 2019 Feb;177:1-5.
 28. Maeda T, Ueta T, Mori E, Yugue I, Kawano O, Takao T, et al. Soft-tissue damage and segmental instability in adult patients with cervical spinal cord injury without major bone injury. *Spine (Phila Pa 1976)*. 2012 Dec 1;37(25):E1560-6.
 29. Martinez-Perez R, Munarriz PM, Paredes I, Cotrina J, Lagares A. Cervical Spinal Cord Injury without Computed Tomography Evidence of Trauma in Adults: Magnetic Resonance Imaging Prognostic Factors. *World Neurosurg*. 2017 Mar;99:192-9.
 30. Na BR, Seo HY. Adult Spinal Cord Injury without Major Bone Injury: Effects of Surgical Decompression and Predictors of Neurological Outcomes in American Spinal Injury Association Impairment Scale A, B, or C. *J Clin Med*. 2021 Mar 6;10(5).
 31. Neva MH, Roeder CP, Felder U, Kiener B, Meier W, Perler M, et al. Neurological outcome, working capacity and prognostic factors of patients with SCIWORA. *Spinal Cord*. 2012 Jan;50(1):78-80.
 32. Ouchida J, Yukawa Y, Ito K, Katayama Y, Matsumoto T, Machino M, et al. Delayed Magnetic Resonance Imaging in Patients With Cervical Spinal Cord Injury Without Radiographic Abnormality. *Spine (Phila Pa 1976)*. 2016 Aug 15;41(16):E981-E6.
 33. Qi C, Xia H, Miao D, Wang X, Li Z. The influence of timing of surgery in the outcome of spinal cord injury without radiographic abnormality (SCIWORA). *J Orthop Surg Res*. 2020 Jun 16;15(1):223.
 34. Qi C, Cao J, Xia H, Miao D, Liu Y, Guo J, et al. Does cervical curvature affect neurological outcome after incomplete spinal cord injury without radiographic abnormality (SCIWORA): 1-year follow-up. *J Orthop Surg Res*. 2022 Jul 26;17(1):361.
 35. Sharma S, Singh M, Wani IH, Sharma N, Singh D. Adult Spinal Cord Injury without Radiographic Abnormalities (SCIWORA): Clinical and Radiological Correlations. *J Clin Med Res*. 2009 Aug;1(3):165-72.
 36. Shen H, Tang Y, Huang L, Yang R, Wu Y, Wang P, et al. Applications of diffusion-weighted MRI in thoracic spinal cord injury without radiographic abnormality. *Int Orthop*. 2007 Jun;31(3):375-83.
 37. Tan J, Hu F, Ou J, Su X, Liu J. Analysis of the Curative Effect and Prognostic Factors of Anterior Cervical Surgery for Spinal Cord Injury without Radiographic Abnormalities. *Evid Based Complement Alternat Med*. 2022;2022:6836966.
 38. Wang Y, Xue Y, Zong Y, Ding H, Li Z, He D, et al. Treatment of Atypical Central Cord Injury Without Fracture or Dislocation. *Orthopedics*. 2015 Jun;38(6):e524-8.
 39. Yaqoob Hakim S, Gamal Altawil L, Faidh Ramzee A, Asim M, Ahmed K, Awwad M, et al. Diagnosis, management and outcome of Spinal Cord Injury without Radiographic Abnormalities (SCIWORA) in adult patients with trauma: a case series. *Qatar Med J*. 2021;2021(3):67.
 40. Zhang JD, Xia Q. Role of Intraoperative Disc Contrast Injection in Determining the Segment Responsible

- for Cervical Spinal Cord Injury without Radiographic Abnormalities. *Orthop Surg*. 2015 Aug;7(3):239-43.
41. Zhu F, Yao S, Ren Z, Telemacque D, Qu Y, Chen K, et al. Early durotomy with duroplasty for severe adult spinal cord injury without radiographic abnormality: a novel concept and method of surgical decompression. *Eur Spine J*. 2019 Oct;28(10):2275-82.
 42. Pang D, Pollack IF. Spinal cord injury without radiographic abnormality in children—the SCIWORA syndrome. *J Trauma*. 1989 May;29(5):654-64.
 43. Crooks F, Birkett AN. Fractures and dislocations of the cervical spine*. *British Journal of Surgery*. 2005;31(123):252-65.
 44. Schneider RC, Cherry G, Pantek H. The syndrome of acute central cervical spinal cord injury; with special reference to the mechanisms involved in hyperextension injuries of cervical spine. *J Neurosurg*. 1954 Nov;11(6):546-77.
 45. Holmes G. The Goulstonian Lectures ON SPINAL INJURIES OF WARFARE: Delivered before the Royal College of Physicians of London. *Br Med J*. 1915 Nov 27;2(2865):769-74.
 46. Roberts TT, Leonard GR, Cepela DJ. Classifications In Brief: American Spinal Injury Association (ASIA) Impairment Scale. *Clin Orthop Relat Res*. 2017 May;475(5):1499-504.
 47. Yamazaki M, Mochizuki M, Ikeda Y, Sodeyama T, Okawa A, Koda M, et al. Clinical results of surgery for thoracic myelopathy caused by ossification of the posterior longitudinal ligament: operative indication of posterior decompression with instrumented fusion. *Spine (Phila Pa 1976)*. 2006 Jun 1;31(13):1452-60.
 48. Fredrickson MD. Acute spinal cord injury management. *J Trauma*. 2007 Jun;62(6 Suppl):S9.
 49. Parizel PM, van der Zijden T, Gaudino S, Spaepen M, Voormolen MH, Venstermans C, et al. Trauma of the spine and spinal cord: imaging strategies. *Eur Spine J*. 2010 Mar;19 Suppl 1(Suppl 1):S8-17.
 50. Djang WT. Radiology of acute spinal trauma. *Crit Care Clin*. 1987 Jul;3(3):495-518.
 51. Atesok K, Tanaka N, O'Brien A, Robinson Y, Pang D, Deinlein D, et al. Posttraumatic Spinal Cord Injury without Radiographic Abnormality. *Adv Orthop*. 2018;2018:7060654.
 52. Bozzo A, Marcoux J, Radhakrishna M, Pelletier J, Goulet B. The role of magnetic resonance imaging in the management of acute spinal cord injury. *J Neurotrauma*. 2011 Aug;28(8):1401-11.
 53. Lammertse D, Dungan D, Dreisbach J, Falci S, Flanders A, Marino R, et al. Neuroimaging in traumatic spinal cord injury: an evidence-based review for clinical practice and research. *J Spinal Cord Med*. 2007;30(3):205-14.
 54. Goradia D, Linnau KF, Cohen WA, Mirza S, Hallam DK, Blackmore CC. Correlation of MR imaging findings with intraoperative findings after cervical spine trauma. *AJNR Am J Neuroradiol*. 2007 Feb;28(2):209-15.
 55. Hayashi K, Yone K, Ito H, Yanase M, Sakou T. MRI findings in patients with a cervical spinal cord injury who do not show radiographic evidence of a fracture or dislocation. *Paraplegia*. 1995 Apr;33(4):212-5.
 56. Shimada K, Tokioka T. Sequential MRI studies in patients with cervical cord injury but without bony injury. *Paraplegia*. 1995 Oct;33(10):573-8.
 57. Boese CK, Lechler P. Spinal cord injury without radiologic abnormalities in adults: a systematic review. *J Trauma Acute Care Surg*. 2013 Aug;75(2):320-30.
 58. Mhuircheartaigh NN, Kerr JM, Murray JG. MR imaging of traumatic spinal injuries. *Semin Musculoskelet Radiol*. 2006 Dec;10(4):293-307.
 59. Pérez-López C, Isla A, Gómez Sierra A, Budke M. Cervical epidural hematoma without fracture in a patient with ankylosing spondylitis. A case report. *J Neurosurg Sci*. 2004 Jun;48(2):91-4; discussion 4.
 60. Grant GA, Mirza SK, Chapman JR, Winn HR, Newell DW, Jones DT, et al. Risk of early closed reduction in cervical spine subluxation injuries. *J Neurosurg*. 1999 Jan;90(1 Suppl):13-8.
 61. Benzel EC, Hart BL, Ball PA, Baldwin NG, Orrison WW, Espinosa MC. Magnetic resonance imaging for the evaluation of patients with occult cervical spine injury. *J Neurosurg*. 1996 Nov;85(5):824-9.
 62. Pang D. Spinal cord injury without radiographic abnormality in children, 2 decades later. *Neurosurgery*. 2004 Dec;55(6):1325-42; discussion 42-3.

63. Kulkarni MV, Bondurant FJ, Rose SL, Narayana PA. 1.5 tesla magnetic resonance imaging of acute spinal trauma. *Radiographics*. 1988 Nov;8(6):1059-82.
64. Ramón S, Domínguez R, Ramírez L, Paraira M, Olona M, Castelló T, et al. Clinical and magnetic resonance imaging correlation in acute spinal cord injury. *Spinal Cord*. 1997 Oct;35(10):664-73.
65. Ehara S, Shimamura T. Cervical spine injury in the elderly: imaging features. *Skeletal Radiol*. 2001 Jan;30(1):1-7.
66. Wilson JR, Cadotte DW, Fehlings MG. Clinical predictors of neurological outcome, functional status, and survival after traumatic spinal cord injury: a systematic review. *J Neurosurg Spine*. 2012 Sep;17(1 Suppl):11-26.
67. Varma A, Hill EG, Nicholas J, Selassie A. Predictors of early mortality after traumatic spinal cord injury: a population-based study. *Spine (Phila Pa 1976)*. 2010 Apr 1;35(7):778-83.
68. Grabb PA, Pang D. Magnetic resonance imaging in the evaluation of spinal cord injury without radiographic abnormality in children. *Neurosurgery*. 1994 Sep;35(3):406-14; discussion 14.
69. Yucesoy K, Yuksel KZ. SCIWORA in MRI era. *Clin Neurol Neurosurg*. 2008 May;110(5):429-33.
70. Dare AO, Dias MS, Li V. Magnetic resonance imaging correlation in pediatric spinal cord injury without radiographic abnormality. *J Neurosurg*. 2002 Jul;97(1 Suppl):33-9.
71. Schaefer DM, Flanders AE, Osterholm JL, Northrup BE. Prognostic significance of magnetic resonance imaging in the acute phase of cervical spine injury. *J Neurosurg*. 1992 Feb;76(2):218-23.
72. Boldin C, Raith J, Fankhauser F, Haunschmid C, Schwantzer G, Schweighofer F. Predicting neurologic recovery in cervical spinal cord injury with postoperative MR imaging. *Spine (Phila Pa 1976)*. 2006 Mar 1;31(5):554-9.
73. Mazaki T, Ito Y, Sugimoto Y, Koshimune K, Tanaka M, Ozaki T. Does laminoplasty really improve neurological status in patients with cervical spinal cord injury without bone and disc injury? A prospective study about neurological recovery and early complications. *Arch Orthop Trauma Surg*. 2013 Oct;133(10):1401-5.
74. Bosch PP, Vogt MT, Ward WT. Pediatric spinal cord injury without radiographic abnormality (SCIWORA): the absence of occult instability and lack of indication for bracing. *Spine (Phila Pa 1976)*. 2002 Dec 15;27(24):2788-800.

Cite this
Paper as



Siatos N, Benetos IS, Evengelopoulos DS, Vlamis J, Evangelopoulou M. Imaging and clinical approaches in the management of patients with spinal cord injury without radiographic abnormality (SCIWORA). *Acta Orthop Trauma Hell* 2024; 75(1): 9-23.