

Femoral head osteonecrosis-imaging findings and differential diagnosis

A. Balanika,¹ Christos Baltas,² Dimitrios Begkas³

¹MD, PhD, MSci, Consultant Radiologist Computed Tomography Department, Department of Musculoskeletal Ultrasound, Department of Osteoporosis, General Hospital of Athens "Asclepieio Voulas"

²MD, PhD, MSci, Consultant Radiologist, Radiology Imaging Department, General Hospital of Athens "G. Gennimatas"

³MD, PhD, Consultant Orthopaedic, 6TH Orthopaedic Dept, General Hospital of Athens "Asclepieio Voulas"

ABSTRACT

This review addresses the imaging features of femoral head osteonecrosis. Although the initial evaluation should include plain radiography in combination with thorough history and physical examination, MRI represents the method of choice for an early detection and correct diagnosis. It is also highlighted the imaging findings that enable differentiation of femoral head osteonecrosis from other pathological conditions including transient osteoporosis and arthritis.

KEYWORDS: Femoral head osteonecrosis, imaging findings, bone marrow edema, hip arthritis

Introduction

Osteonecrosis of the femoral head is a common disease caused by ischemia or disruption of the blood flow of the epiphyseal-subchondral bone [1], resulting in bone loss and weakening of the femoral head with complications such as fracture and osteoarthritis. It most often affects males, aged 30-50 years with bilateral involvement up to 72% [2]. The etiology is uncertain: idiopathic causes (37%), systemic diseases, trauma, corticosteroids and alcohol abuse [3].

Pathogenesis and Clinical Manifestations

Genetic predisposition, metabolic and local factors can compromise the microvascular circulation

of the femoral head leading to bone necrosis that affects first the hematopoietic cells, then the bone cells and finally the fat cells [4]. The reparative process involves peripheral revascularization of the ischemic area with activation of osteoclasts and osteoblasts leading to osteopenia and new bone formation. Subsequently, cell migration takes place from the periphery of the lesion to the necrotic center to repair the damaged area [5,6]. The complications of the above procedure concern the formation of abnormal, mechanically weak bone, prone to subchondral fractures and subsequent osteoarthritis of the hip [7].

The most common symptom is acute hip pain located mainly in the groin radiating to the thighs

CORRESPONDING
AUTHOR,
GUARANTOR

Alexia Balanika, MD, PhD, MSci
tel: 6977472359
email: mpalanika@hotmail.com,

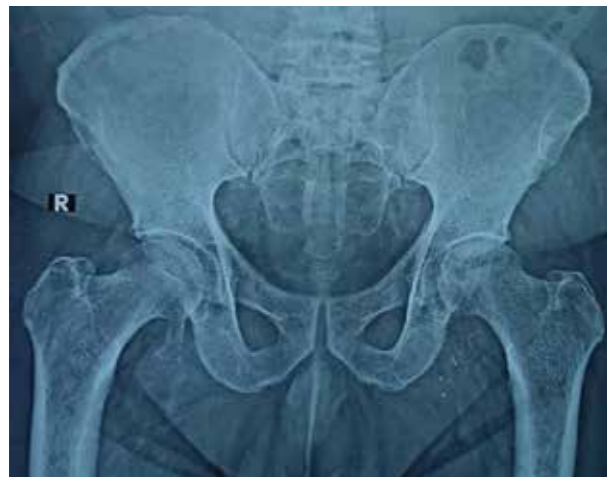

Figure 1. X-ray of pelvis and hip show a stage-II osteonecrosis of the left femoral head -crescent sign

or buttocks, followed by functional impairment. Negative inflammatory markers and absence of fever help to differentiate femoral head osteonecrosis from inflammatory and septic arthritis. A normal plain hip radiography excludes hip arthropathy from the diagnosis at initial stages [8].

Classification

Among the multiple classification systems have been proposed for femoral head osteonecrosis the most commonly used are: 1) Ficat and Arlet, 2) University of Pennsylvania/Steinberg, 3) Association Research Circulation Osseous (ARCO) [9,10]. Ficat and Arlet is the simplest classification system developed in 1964. It was based on radiographic findings to stage the disease, without considering the size or location of the osteonecrotic lesion, two important factors which are used nowadays to predict the therapeutic outcome [11]. The Steinberg system and the Association for Research on Bone Circulation (ARCO) systems were designed in 1985 and 1994 respectively and included computed tomography (CT) and magnetic resonance imaging (MRI) findings to diagnose disease in early stage [12].

According to the classification systems, plain radiography has been shown to be inaccurate in assessing the degree of femoral head depression, overestimating ARCO stage II and underestimating ARCO stage III lesions [13]. Therefore, it is useful

in assessing the degree of femoral head collapse after stage III of the ARCO classification system [14], MRI is useful for diagnosing disease in stages prior to collapse of the femoral head, distinguishing early from advanced disease, and quantifying the osteonecrotic lesion (location and size) [15].

Imaging findings

The plain radiograph findings according to the Ficat and Arlet system [11] include: stage 0: normal radiograph, stage I: normal radiograph and acute hip pain, stage II: sclerosis, osteopenia and cystic changes in the femoral head with preservation of its shape and the hip joint space, stage III: radiographic crescent sign - subchondral lucent line on the femoral head - with preservation of its shape and the hip joint space and stage IV: flattening of the femoral head and hip joint arthropathy (Fig.1). The same applies to CT, with the method being more sensitive in advanced stages, especially in stage III that can detect easily subchondral fractures and femoral head collapse. At CT a sclerotic line is seen, separating necrotic from viable bone [16].

Bone scintigraphy is used for diagnosis when plain radiography is normal and MRI is contraindicated. It has high sensitivity in detecting multifocal lesions, however due to low spatial resolution and low sensitivity it cannot be used for the quantification of the lesion [17].

MRI achieves excellent sensitivity and specificity for detecting the disease at early stages and is considered the method of choice for staging and quantification of the lesion, particularly when the plain radiography is negative, as well as for the follow up [15]. The Mitchell et al. [18] classification is commonly used for staging of the disease. The hall-mark of the disease is a sclerosing hypointense "band-like" lesion of the femoral head in axial MR-images. The pathognomonic finding is a serpentine rim on T2-weighted images, the "double line sign" (Fig.2). Its outer rim corresponds to reactive tissue of low signal intensity on T2-weighted images and the inner rim to hyperintensity vascular-regenerative tissue at the necrotic-viable interface of the lesion. The inner central area shows low, iso - and high signal intensity compared to normal

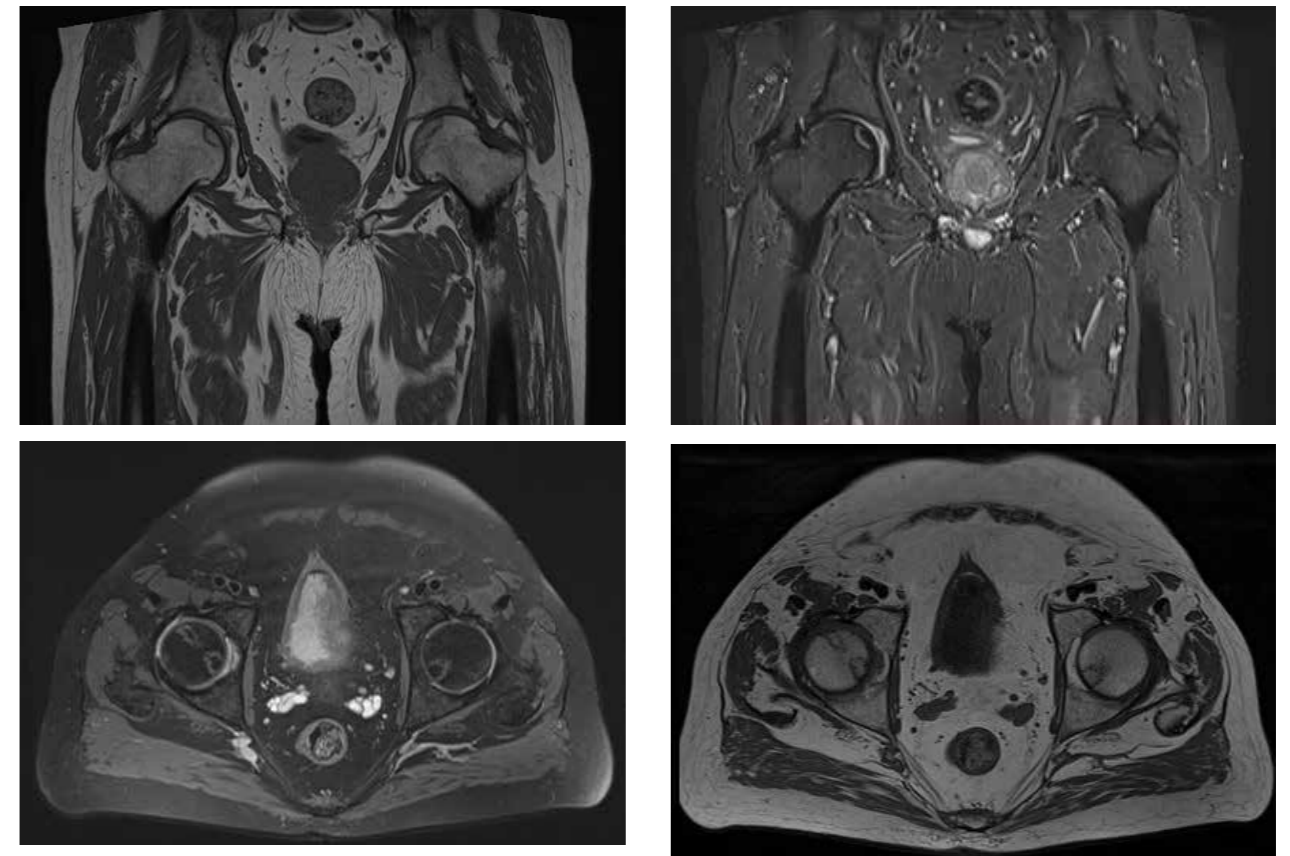


Figure 2. Axial and Coronal T1 and STIR images show bilateral femoral head osteonecrosis-double line sign.

bone marrow depending on the stage of the disease [16]. Paramagnetic contrast media administration can be used preoperatively to evaluate the contour of the femoral head and postoperatively to monitor the vascularized graft [19].

Joint fluid collection is seen in 50% of all cases. Bone marrow edema is not a finding in the early stages of the disease [20] and it is never seen before the presence of the band-like sign [21]. Its appearance correlates significantly with the onset and progressive worsening of the pain. It is a poor prognostic sign as it is related to subsequent collapse of the femoral head (Fig.3) [22]. The presence of subchondral fractures is a complication in femoral head osteonecrosis. They are seen as smooth low signal intensity areas on T1-weighted images, concave to articular surfaces extending along the whole necrotic region.

Staging and Quantification

The size of the necrosis is an important factor

in determining disease prognosis and therapeutic management. Various quantification methods have been developed to characterize the size/location of the necrosis and at the moment three systems are widely used: Steinberg classification, Japanese Investigation Committee (JIC) classification and modified Kerboul classification [23]. In the Steinberg System the extent of involvement is estimated as a percentage of the articular surface or the femoral head area (< 15% of articular surface or head affected), moderate (15-30%), and severe (> 30%) [24]. In the JIC classification, the extent of femoral head involvement is estimated as the percentage of the weight-bearing area on the mid-coronal T1-weighted image: type A lesion < medial 1/3 of weight-bearing area, type B lesion < medial 2/3 of weight-bearing area, type C1 lesion > medial 2/3 of weight bearing area without exceeding the acetabular rim and type C2 lesion exceeding the acetabular margin [25]. In the modified Kerboul classifi-

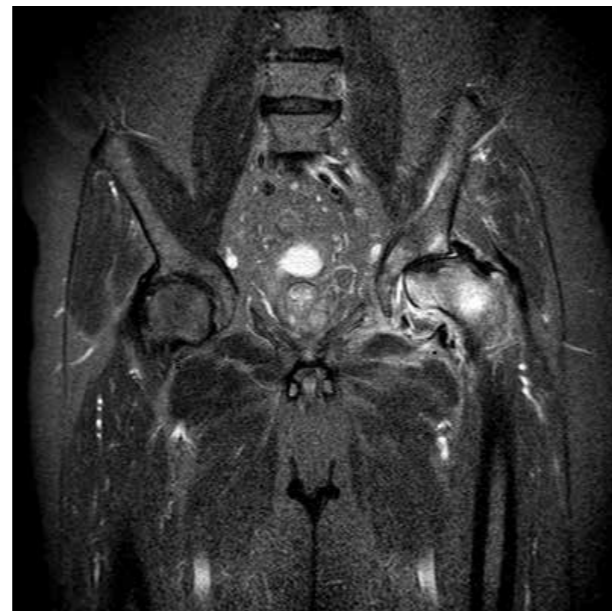
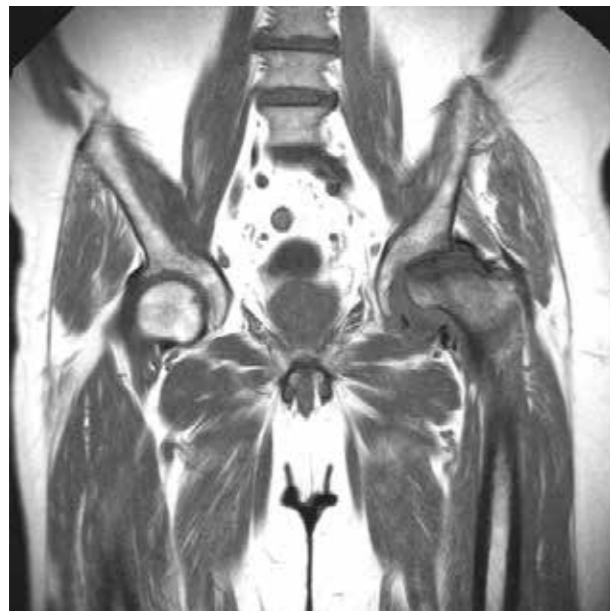
Figure 3. Axial and Coronal T1 and STIR images show late-stage left femoral head osteonecrosis with femoral head flattening and hip arthropathy.

cation system, the extent of necrosis is quantified by the combined angle of the necrotic portion on the mid-coronal and mid-sagittal MR images of the femoral head. The system distinguishes three categories: small lesions (combined necrotic angle < 190°), medium-sized lesion (combined necrotic angle between 190° and 240°), and large lesion (combined necrotic angle > 240°) with increased risk of femoral head collapse at the medium and large sized lesions [26,27].

The radiological report for the diagnosis of osteonecrosis and for treatment planning should include the following: 1) the site of necrosis, 2) the stage of necrosis, 3) the presence of a subchondral fracture, 4) the degree of collapse of the articular surface (critical point >2 mm) and 5) the quantification of necrosis (Table I).

Differential diagnosis

The differential diagnosis on MR imaging includes a) potential pitfalls (persistent red marrow, fovea centralis, synovial herniation pits) and b) pathological conditions (subchondral cysts, idiopathic transient osteoporosis, subchondral insufficiency fractures, stress injuries, arthritis) that can misinterpret as femoral head osteonecrosis.

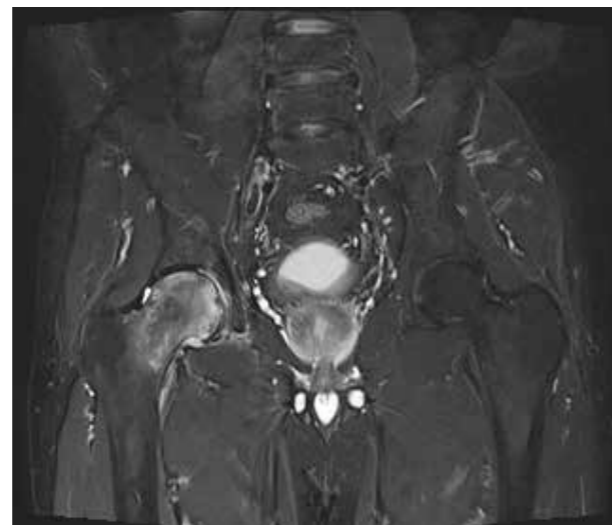


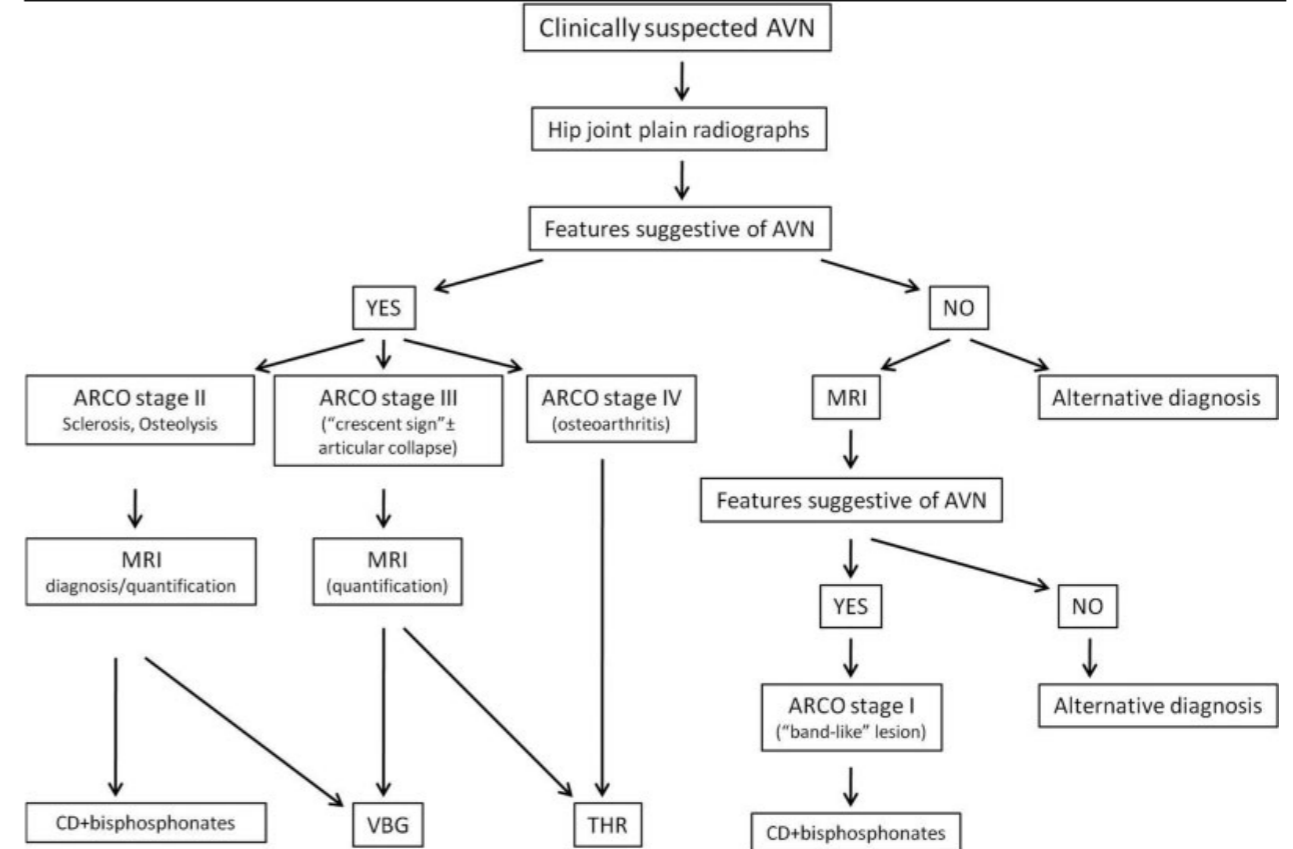
Figure 4 TOH. Coronal STIR image shows right femoral head and neck bone marrow edema-sparing sign

Persistent red marrow: The presence of red marrow in the subchondral region of the femoral head is found more often in women. Normal red marrow signal intensity is higher than of adjacent muscle, whereas in femoral head osteonecrosis, T1-weighted signal intensity of the involved area is lower than that of adjacent muscle [28].

Fovea centralis: The central fovea represents the

TABLE 1.

ARCO proposed algorithm about the correlation of imaging findings and treatment planning



normal anatomic attachment of the ligamentum teres and it is demonstrated as a low-signal indentation on the medial rim of the femoral head (3 o'clock on axial MR images) [28].

Herniation pits: It is a benign lesion that resembles a subchondral cyst. The lesion is typically located at the 10 and 2 o'clock position in the subchondral region of the femoral head, a fact that helps distinguish it from AVN [29].

Transient osteoporosis (TOH): It occurs more often in middle-aged men and women in the perinatal period, without a history of trauma, and it is always unilateral [30] in contrast to the more common bilateral involvement of femoral head osteonecrosis [31]. Radiography typically shows severe osteopenia and cortical bone loss in the femur within 5 weeks of the onset of symptoms. Constant finding on spinal and hip DXA is osteo-

penia or osteoporosis. MRI shows bone marrow edema in the early phase of the disease with imaging findings becoming apparent in about the first 48 hours. A pathognomonic sign (the "sparing" sign) is the presence of extensive bone marrow edema sparing the inferior medial part of the femoral head and the greater trochanter and is visualized in 90% of patients at approximately 4 to 6 weeks (Fig.4) [32]. After intravenous contrast injection there is marked enhancement of the hip joint due to reactive synovitis. In TOH, subchondral fractures are described in up to 49% patients and they are seen as irregular, thin lines deep in the articular surface, often discontinuous, with low signal intensity in all sequences. However MR signal characteristics of the necrotic area in femoral head osteonecrosis varies according to the stage of the disease. Finally, the imaging


findings of TOH resolve spontaneously within 6-9 months after weight-bearing restriction and analgesic therapy [30].

Stress injuries: They are stress fractures (more common in athletes) or insufficiency fractures (over the age of 60) [28]. Plain radiograph may initially be normal on MRI, bone marrow edema and periarticular tissue edema are initially visualized, and then a low-signal linear or curvilinear fracture line on all sequences appear in the medial subchondral region of the femoral head [31]. In equivocal cases a history of trauma and the presence of osteopenia may help in the differential diagnosis from femoral head osteonecrosis.

Infectious and inflammatory diseases: An unexplained monoarticular joint-fluid collection in high-risk individuals (immunosuppression, renal failure, DM, intravenous drug users) raises the suspicion of septic arthritis. MR imaging abnormalities present

within the first 24 hours after the onset of symptoms (diffuse reactive bone marrow edema, joint fluid collection, periarticular edema, enhancement by paramagnetic substance, abscesses and myositis) [32]. In rheumatoid arthritis, the presence of bone marrow edema is an early MR finding. The presence of bone erosions and arthritis contribute to the differential diagnosis from femoral head osteonecrosis [33]. Early hip involvement in ankylosing spondylitis is depicted as subchondral bone marrow edema usually anteriorly in location, suggesting enthesopathy [34].

Conclusion

Early diagnosis and staging of osteonecrosis of femoral head is becoming increasingly important for early and effective treatment of the disease. History and predisposing factors combined with timely MR imaging contribute to the differential diagnosis from other pathologic mimickers. 

REFERENCES

- Mirzai R, Chang C, Greenspan A, Gershwin ME. Avascular necrosis. *Comprehensive therapy* 1998; 24: 251-5.
- Assouline-Dayan Y, Chang C, Greenspan A, et al. Pathogenesis and natural history of osteonecrosis. *Semin Arthritis Rheum* 2002; 32(02): 94-124.
- Murphey MD, Foreman KL, Klassen-Fischer MK, et al. From the radiologic pathology archives imaging of osteonecrosis: radiologic-pathologic correlation. *Radiographics: a review publication of the Radiological Society of North America, Inc.* 2014; 34: 1003-28.
- Chang CC, Greenspan A, Gershwin ME. Osteonecrosis: Current perspectives on pathogenesis and treatment. *Semin Arthritis Rheum* 1993; 23(1): 47-69.
- Mont MA, Pacheco IH, Hungerford DS. Non-traumatic osteonecrosis of the femoral head: part I. Demographics, pathogenesis, diagnosis and staging. *Bombay Hospital Journal* 1996;38.
- Ohzono K, Saito M, Takaoka K, et al. Natural history of nontraumatic avascular necrosis of the femoral head. *The Journal of bone and joint surgery. British volume* 1991; 73: 68-72.
- Seamon J, Keller T, Saleh J, Cui Q. The pathogenesis of nontraumatic osteonecrosis. *Arthritis* 2012; 2012: 601763.
- Manaster BJ. From the RSNA Refresher Courses. *Radiological Society of North America. Adult chronic hip pain: radiographic evaluation. Radiographics: a review publication of the Radiological Society of North America, Inc.* 2000; 20 Spec No: S3-S25.
- Mont M, Marulanda G, Jones LC, et al. Systematic analysis of classification systems for osteonecrosis of the femoral head. *J Bone Joint Surg* 2006; 88-A-(Supplement 3): 16-26.
- Steinberg ME, Steinberg DR. Classification systems for osteonecrosis: an overview. *Orthop Clin N Am* 2004; 35: 273-83.
- Ficat RP. Idiopathic bone necrosis of the femoral head: early diagnosis and treatment. *J Bone Joint Surg Br* 1985; 67-B(1): 3-9.
- ARCO (Association Research Circulation Osseous). Committee on terminology and classification. *ARCO News* 1992; 4: 41-46.
- Zibis AH, Karantanas AH, Roidis NT, et al. The role of MR imaging in staging femoral head osteonecrosis. *Eur J Radiol* 2007; 63(01): 3-9.

- Vassalou E, Spanakis K, Tsifountoudis I, Karantanas A. MR Imaging of the Hip: An Update on Bone Marrow Edema. *Seminars in Musculoskeletal Radiology* Vol. 23 No. 3/2019.
- Karantanas AH. Accuracy and limitations of diagnostic methods for avascular necrosis of the hip. *Expert opinion on medical diagnostics* 2013; 7: 179-87.
- Azzali E, Milanese GI, Martella I, et al. Imaging of osteonecrosis of the femoral head *Acta Biomed* 2016; Vol. 87, Supplement 3: 6-12.
- Dasa V, Abdel-Nabi, Anders M, et al. F-18 fluoride positron emission tomography of the hip for osteonecrosis. *Clin Orthop Relat Res* 2008; 466: 1081-6.
- Mitchell DG, Rao VM, Dalinka MK, et al. Femoral head avascular necrosis: correlation of MR imaging, radiographic staging, radionuclide imaging, and clinical findings. *Radiology* 1987; 162: 709-15.
- Malizos KN, Karantanas AH, Varitimidis SE, et al. Osteonecrosis of the femoral head: Etiology, imaging and treatment. *European Journal of Radiology* 2007; 63: 16-28.
- Kim YM, Oh HC, Kim HJ. The pattern of bone marrow oedema on MRI in osteonecrosis of the femoral head. *J Bone Joint Surg Br* 2000; 82B: 837-41.
- Fujioka M, Kubo T, Nakamura F, et al. Initial changes of non-traumatic osteonecrosis of femoral head in fat suppression images: bone marrow edema was not found before the appearance of band patterns. *Magn Reson Imaging* 2001; 19: 985-91.
- Ito H, Matsuno T, Minami A. Relationship between bone marrow edema and development of symptoms in patients with osteonecrosis of the femoral head. *AJR* 2006; 186: 1761-70.
- Hines J.T. Osteonecrosis of the Femoral Head: an Updated Review of ARCO on Pathogenesis, Staging and Treatment. *J Korean Med Sci.* 2021; 36(24): e177.
- Steinberg ME, Brighton CT, Steinberg DR, et al. Treatment of avascular necrosis of the femoral head by a combination of bone grafting, decompression, and electrical stimulation. *Clin Orthop Relat Res* 1984; (186): 137-53.
- Nishii T, Sugano N, Ohzono K, Sakai T, Sato Y, Yoshikawa H. Significance of lesion size and location in the prediction of collapse of osteonecrosis of the femoral head: a new three-dimensional quantification using magnetic resonance imaging. *J Orthop Res* 2002; 20(1): 130-6.
- Kerboul M, Thomine J, Postel M, Merle d'Aubigné R. The conservative surgical treatment of idiopathic aseptic necrosis of the femoral head. *J Bone Joint Surg Br* 1974; 56-B(2): 291-6.
- Ha YC, Kim HJ, Kim SY, et al. Effects of age and body mass index on the results of transtrochanteric rotational osteotomy for femoral head osteonecrosis. *J Bone Joint Surg Am* 2010; 92(2): 314-21.
- Jackson SM, Major MN. Pathologic conditions mimicking osteonecrosis. *Orthop Clin N Am* 2004; 35(3): 315-20.
- Nokes SR, Vogler JB, Spritzer CE, et al. Herniation pits of the femoral neck: appearance at MR imaging. *Radiology* 1989; 172: 231-4.
- Vande Berg BC, Malghem JJ, Lecouvet FE, et al. Idiopathic bone marrow edema lesions of the femoral head: predictive value of MR imaging findings. *Radiology-* 1999; 212(2): 527-35.
- Khurana B, Okanobo H, Ossiani M, et al. Abbreviated MRI for patients presenting to the emergency department with hip pain. *AJR Am J Roentgenol* 2012; 198(06): W581-8.
- Karchevsky M, Schweitzer ME, Morrison WB, Parellada JA. MRI findings of septic arthritis and associated osteomyelitis in adults. *AJR Am J Roentgenol* 2004; 182(01): 119-22.
- McQueen FM. The use of MRI in early RA. *Rheumatology (Oxford)* 2008; 47(11): 1597-99.
- Vander Cruyssen B, Muñoz-Gomariz E, Font P, et al; ASPECTREGISPONSER-RESPONDIA working group. Hip involvement in ankylosing spondylitis: epidemiology and risk factors associated with hip replacement surgery. *Rheumatology (Oxford)* 2010; 49(01): 73-81.

READY - MADE
CITATION

Balanika A, Baltas C, Begkas D. Femoral head osteonecrosis-imaging findings and differential diagnosis. *Acta Orthop Trauma Hell* 2023; 74(3): 21-27.