

Fracture of femoral neck in modular total hip arthroplasty: Report of 3 cases and review of the literature.

Panagopoulos A, Solou K, Tatani I, Tatarakis D, Megas P.

Department of Adult Reconstruction, Orthopaedic Clinic, Patras University Hospital, Greece

ABSTRACT

Modular stems offer to surgeons the flexibility to adjust intraoperatively the femoral neck version independently of individual femoral geometry that theoretically can minimize the bearing surface wear, potential implant loosening and the rate of dislocation. Excellent functional outcomes and survivorship rates of modular stems has been reported in the literature but increasing modularity also renders several postulated disadvantages such as implant fracture, fretting and galvanic corrosion, pseudotumor formation and increased rate of revisions for stem loosening, dislocation and adverse local tissue reactions. We report here three cases of modular femoral neck fractures in patients who underwent a primary total hip arthroplasty in our department and also, we present a systematic review of similar cases in the literature trying to identify the incidence and the main risk factors.

KEY WORDS: Modular THA, fracture of the neck, corrosion, revision

Introduction

Modular stems in Total Hip Arthroplasty (THA) have been introduced to provide an anatomic restoration of native hip biomechanics, especially the femoral offset, that theoretically can minimize the bearing surface wear, potential implant loosening and the rate of dislocation [1-3]. Excellent mid- and long-term functional outcomes and survivorship of modular stems has been reported in the literature [4,5] but increasing modularity also renders several postulated disadvantages such as implant fracture,

fretting and galvanic corrosion, pseudotumor formation and increased rate of revisions for stem loosening, dislocation and adverse local tissue reactions [6-8].

Modular neck fracture carries an estimated incidence of 0.26% and is considered a severe complication of modular THA as it usually requires a major revision stem surgery in an otherwise well-fixed femoral component [9-12]. We report three cases of modular femoral neck fractures in patients who underwent a primary THA in our department and

CORRESPONDING
AUTHOR,
GUARANTOR

Andreas Panagopoulos MD, PhD
Associate Professor in Orthopaedics, Patras University Hospital
Papanikolaou1, Rio-Patras, 26504, Greece
Tel: +302613603555, +306944363624
Email: andpan21@gmail.com

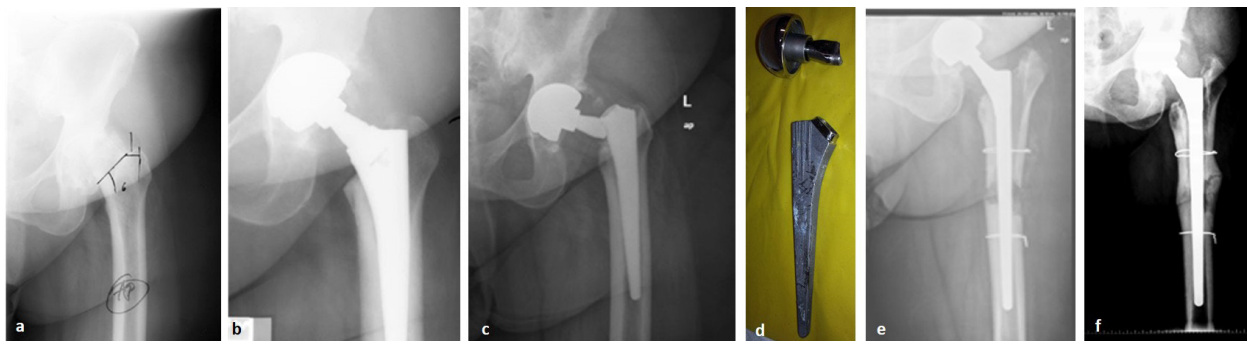


Figure 1. (a) preoperative x-ray of a 44-year-old patient with osteoarthritis, hip dysplasia and slipped capital femoral epiphysis, (b) 2-month postoperative x-ray after THA implantation, (c) fracture of the femoral neck at 4 years postoperatively, (d) intraoperative photo of the broken implant, (e) 3-month postoperative x-ray after revision surgery with a Wagner type stem and extended osteotomy and (f) last follow up x-ray at 3 years post-revision.

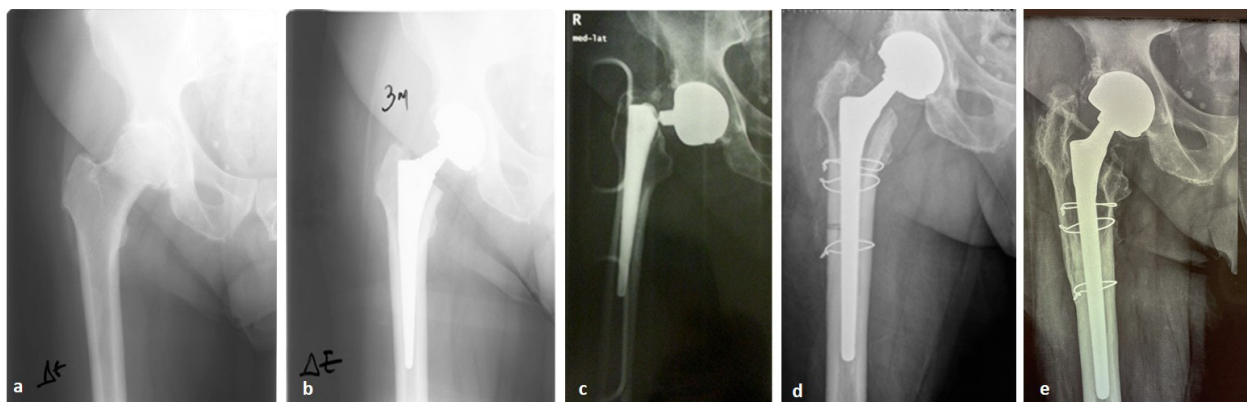


Figure 2. (a) preoperative x-ray of a 64-year-old patient with osteoarthritis of the hip, (b) 3-month postoperative x-ray after THA implantation, (c) fracture of the femoral neck at 5 years postoperatively, (d) 1-month postoperative x-ray after revision surgery with a Wagner type stem and extended osteotomy and (e) last follow up x-ray at 11 years post-revision.

also, we present a systematic review of similar cases in the literature.

Cases Presentation

Case 1: A 44-year-old woman, with a BMI of 27.2 and a clear medical history, underwent a left THA in our department due to severe osteoarthritis in the presence of congenital hip dysplasia and slipped capital femoral epiphysis (Fig 1a). Through a mini-posterior approach, a metal-on-metal prosthesis was applied, with a 50 mm CONSERVE MOM acetabular shell, 44 mm medium metal head, and a no. 6 PRO-FEMUR®-L femoral stem with modular AR/VV 2 long-neck (Wright Medical Technology, Arlington,

TN, USA) [Fig 1b]. The regular annual follow-up indicated undisputable integration of the prosthesis and excellent clinical performance. Four years later, she attended the Emergency Department with acute left hip pain and inability for weight bearing. Until that moment, no complications or symptoms by the THA were mentioned and full compliance to all respective instructions and restrictions was reported. On clinical examination she had pain during motion, restricted ROM and shortening of the left limb. Radiological control revealed a fracture of the femoral stem at the neck-stem junction area (Fig 1c). Two days later, she underwent revision THA through the old posterior approach. The fem-

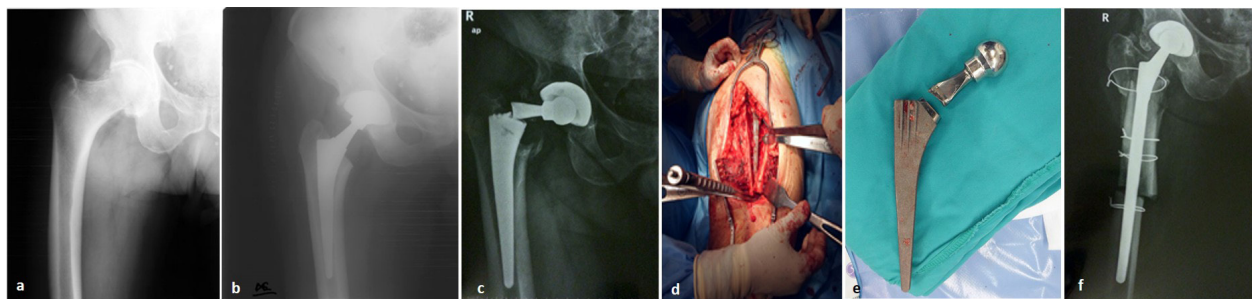


Figure 3. (a) preoperative x-ray of a 64-year-old patient with hip osteoarthritis, (b) 15-days postoperative x-ray after THA implantation, (c) fracture of the femoral neck at 6 years postoperatively, (d,e) intraoperative photos of the extended osteotomy and the broken implant, (f) 3-month postoperative x-ray after revision surgery with a Wagner type stem.

oral stem (Fig. 1d) was firmly integrated and was revised with an open book femoral osteotomy using a cementless Wagner 16mm/265mm prosthesis (Zimmer GmbH, Winterthur, Switzerland) with a short neck and a 44 mm metal head (Fig 1e). Two cerclage wires were used for femoral osteosynthesis. Intraoperative cultures revealed the presence of *Enterococcus Faecium* and the patient was hospitalized for 3 weeks receiving intravenously linezolid and meropenem. She was discharged afebrile following the usual mobilization protocols. At the 3-year follow up appointment (Fig. 1f) she had normal range of hip motion, painless weight-bearing, no limb-length discrepancy and she demonstrated a Harris-Hip score of 90.

Case 2. A 64-year-old man, with a BMI of 32.3, a medical history of Diabetes, Hyperlipidemia and Arterial Hypertension, underwent a right THA in our department because of primary hip osteoarthritis (Fig 2a). Through a mini-posterior approach an uncomplicated metal-on-metal prosthesis was applied, with 54mm CONSERVE MOM acetabular shell, 48mm medium metal head, and a no. 5 PROFEMUR-L® femoral stem with a long, high offset neck (Wright Medical Technology, Arlington, TN, USA). The postoperative follow-up up to 3 years indicated undisputable integration of the prosthesis and excellent clinical outcome (Fig 2b). Five years later, the patient was transferred to our hospital after a sudden right hip pain and subsequent fall at his home with inability to bear weight thereafter. Until that moment, no complications or symp-

toms by the THA were mentioned and full compliance to all respective instructions and restrictions was reported. The clinical examination revealed restricted ROM at the right hip, shortening of the right limb and weight bearing inability, because of the acute pain in the area. No other symptoms or signs were reported. The radiological examination revealed a fracture of the femoral stem at the femoral neck-stem junction area (Fig 2c). Three days later he underwent revision right THA through the old posterior approach. The femoral stem was firmly integrated and revised, via an open book femoral osteotomy, to a cementless Wagner 16mm/265mm femoral stem with a standard neck and a 48mm metal head. Three cerclage wires were used for the femoral osteosynthesis and 2 Ethibond no.5 sutures for stabilization of the greater trochanter. The postoperative x-ray control of the revised femoral stem indicated an acceptable femoral osteosynthesis and mounting of the new prosthesis (Fig 2d). The patient was hospitalized for 9 days in total and was released following the usual mobilization protocols. At his last follow up evaluation, 11 years post revision surgery (Fig 2e) he had a painless hip motion, 1 cm length discrepancy without any compromise during walking and a Harris Hip Score of 87.

Case 3. A 64-year-old man with a BMI of 33.4, a medical history of chronic renal failure, left pyonephrosis (fistula), arterial hypertension, eye cataract and hyperuricemia, underwent a right THA because of primary osteoarthritis of his right hip (Fig 3a). Through a mini-posterior approach, an uncom-

TABLE 1.

Case reports of modular stem fractures in the literature

Study / (year)	No pts	Implant type	Gender	Age	BMI	Failure (m)	Symptoms
1. Lee ¹⁵ (2001)	2	Exactech Exactech	male male	69 53	29.3 36	43 45	sudden pain sudden pain
2. Botti ¹⁶ (2005)	1	AML; DePuy	male	90	27.2	176	one month pain
3. Skendzel ²⁷ (2010)	2	Profemur Z Profemur Z	male male	55 67	31.2 34.6	44 29	Hip pain, creaking, sudden sensation of hip instability Hip pain, inability to ambulate, creaking
4. Wilson ³³ (2010)	1	Profemur Z	male	62	25.6	25	sudden hip pain and inability
5. Wright ³⁴ (2010)	1	Profemur Z	male	49	39.3	44	fall from standing height
6. Atwood ³⁵ (2010)	1	Profemur Z	male	30	29	22	fall from standing height
7. Dangles ³⁶ (2010)	1	Wright	male	66	NA	42	sudden hip pain and inability
8. Kohler ³⁷ (2010)	2	Metha Metha	male male	69 52	27.8 27.2	18 20	sudden hip pain sudden hip pain
9. Paliwal ³⁸ (2010)	1	Acumatch M-series	male	43	36.5	38	NA
10. Gilbert ³⁹ (2011)	1	Profemur Z	male	56	NA	72	sudden hip pain
11. Vučajnk ¹⁷ (2012)	1	GSP	male	56	31.6	144	fall from standing height
12. Ellman ¹⁸ (2013)	1	Profemur Z	male	59	29.6	60	hip and groin pain, clicking, subjective instability
13. Sotereanos ¹⁹ (2013)	1	Kinectiv stem (Zimmer)	male	49	36.6	15	step off 0.5 m truck - pain
14. Mencièrè ²⁰ (2014)	1	ProfemurL	female	66	28.7	22	physical activity - hip instability
15. Baratz ²¹ (2014)	1	Meridian	female	61	32.4	87	sudden hip pain
16. Hernandez ²² (2015)	1	Profemur	male	53	28	42	Sudden hip pain
17. Trieb ²³ (2015)	1	NA	female	60	32.27	144	Fall
18. Fokter ²⁴ (2016)	6	Profemur M GSP Profemur Z Profemur Z Profemur Z GSP	male male male male male male	53 42 54 57 37 56	28 30 33 35 34 32	42 37.2 27.6 62.4 72 144	sudden hip pain sudden hip pain sudden hip pain sudden hip pain sudden hip pain sudden hip pain
19. Fokter ²⁵ (2016)	1	Profemur Z	female	54	39.4	93.6	sudden hip pain
20. Ceretti ²⁶ (2016)	1	Metha	female	43	38.6	29	sudden hip pain and inability, clicking
21. Uchiyama ²⁸ (2017)	1	MODULUS	Female	47	32.8	44	carry weight - sudden pain - hip instability
22. Murena ²⁹ (2019)	2	Profemur L Profemur	male male	48 77	28.02 28.73	48 48	jump from 1m height - crack sudden hip pain
23. Regis ³⁰ (2019)	1	SCL stem	male	64	32.6	144	fall from standing height
24. Lanzuti ³¹ (2019)	1	Profemur Gladiator	male	66	27.8	45	NA
25. Fokter ³² (2021)	1 (bilateral)	An.C.A. Fit An.C.A. Fit	male	38	31.5	240 (R) 36 (L)	sudden hip pain sudden hip pain

plicated metal-on-polyethylene prosthesis was applied with a 54mm PERFECTA acetabular shell, 28 acetabular liner, 28mm/10.5 metal head, and a no. 6 PROFEMUR-L® femoral stem with modular AR 15° long neck (Wright Medical Technology, Arlington, TN, USA). The postoperative x-ray control of the THA indicated a totally acceptable mounting and orientation of the prosthesis (Fig 3b). The patient was hospitalized for 7 days, with no postoperative complications and he followed the usual mobilization protocols having an excellent clinical and radiological outcome at his annual examinations. Six years later, he experienced an acute right hip pain while dancing and he fell to the ground being unable for full weight bearing. Until that moment, no complications or symptoms by the THA were mentioned and full compliance to all respective instructions and restrictions was reported. He was transferred to the hospital whereas a radiological control of the right hip revealed a fracture of the femoral stem at the femoral neck-stem junction area (Fig 3c). Three days later he underwent revision right THA through the old posterior approach. The femoral stem was fully integrated and an extended femoral osteotomy was performed (Fig 3d,e) for removal. A cementless Wagner 17mm/265mm femoral stem prosthesis with a standard neck and 28mm standard metal head was applied. Four cerclage wires were used for the femoral and greater trochanter osteosynthesis. There were no intraoperative complications, and the postoperative x-ray control of the revised femoral stem indicated an acceptable femoral osteosynthesis and mounting of the new prosthesis (Fig 3f). The patient was hospitalized for 17 days because of a substantiated urinary tract infection with *Pseudomonas Aeruginosa* and was discharged following the usual mobilization protocols. At his last follow up 9 years postoperatively, he demonstrated a Harris-Hip score of 90 but he refused to undergo a new radiological examination.

Discussion

Modular stems offer to surgeons the flexibility to adjust intraoperatively the neck version and limb length independently of stem size and individual

femoral geometry. Satisfying functional outcomes have been demonstrated by single center studies after primary THA with modular femoral stems; Vanbiervliet et. al. [13] presented a 100% survivorship of the implant (stem and modular neck) at a mean of 6.5 years without reporting signs of osteolysis or calcar resorption, radiolucent lines, either at the stem-cement or cement-bone interface or important stem subsidence. Krishnan et. al. [14] stated that there is insufficient evidence to confirm the perceived benefits of THA modularity as the additional metal junction is vulnerable to mechanical failure, component disassociation and mechanically assisted crevice corrosion. Other studies [1,6,7] have demonstrated acceptable mid-term clinical results presenting a profile of high risk of early implant failure in males with high BMI, requiring larger neck, offset or head and CoCr material. The published overall complication and revision rate of modular femoral stems are 3.95% and 6.5%, in respect [1, 6]. Colas et al. [8] reported an increased hazard ratio (1.26%) of revision in 324.108 patients with modular stems, using the French national health-insurance databases; after dealing with cause-specific revision, exchangeable neck THAs had a higher incidence of revision for implant failure or periprosthetic fracture (1.68%), and for mechanical complications (1.27%).


Our systematic literature review revealed a total of 25 articles including 35 cases of modular neck fractures after primary THA in 34 patients [15-39] (Table 1). In 20/35 cases the fractured stem was of a PROFEMUR type (Wright Medical Technology, Arlington, TN, USA). The mean age of the patients in the primary THA was 55.85±2.05 years, 28 patients (82.35%) were male, the average BMI was 31.63±0.68 kg/m² and the majority of the modular necks were long (29/35: 82.85%). The incidence of modular neck fracture occurred in average 64.53±8.8 months after the primary THA. Most of the patients (24: 68.6%) referred an atraumatic cause, presented with sudden hip pain and hip instability. The treatment consisted of revision procedure; in 27 (77.1%) of the cases the surgeons reported inability to remove the modular neck from the femoral component, thus extended tro-

chanteric osteotomy was needed in order to revise the femoral component.

With the exception of the young female patient with a normal BMI, the other two patients demonstrated all the proposed risk factors for neck fracturing: male gender, > BMI, long modular neck. All of them did not report previously any sign of thigh or hip pain, squeaking or instability and underwent an extended trochanteric osteotomy for stem exchange with good final outcome. Other risk factors that could affect the neck area of the modular femoral stems are the increased lateral offset, varus stem positioning and inconsistency in the assembly of modular heads due to the force of impaction, the vector of applied force and the contamination of the interface as well as defects in welding of neck to

the prosthesis, the heavy laser etching in the region and the crevice corrosion in the head-neck junction [15,16,39-41].

Conclusion

THA modularity can restore the native hip biomechanics and provide excellent clinical outcome and survivorship, however there is a group of patients in which surgeons should be cautious selecting modular stems due to the increased risk of modular neck fracture. Male patients with increased BMI, and long modular necks should be followed up closely with serial x-rays for early signs of corrosion. If a fracture occurs, an extended osteotomy should be planned for stem revision as usually the broken neck cannot be removed. 

REFERENCES

1. Solarino G, Vicenti G, Carrozzo M, Ottaviani G, Moretti B, Zagra L. Modular neck stems in total hip arthroplasty: current concepts. *EFORT Open Rev.* 2021;6(9):751-758. doi: 10.1302/2058-5241.6.200064.
2. Duwelius PJ, Burkhart B, Carnahan C, Branam G, Ko LM, Wu Y, et al. Modular versus nonmodular neck femoral implants in primary total hip arthroplasty: Which is better? *Clin Orthop Relat Res.* 2014;472(4):1240-5. doi: 10.1007/s11999-013-3361-4.
3. Omlor GW, Ullrich H, Krahmer K, Jung A, Aldinger G, Aldinger P. A stature-specific concept for uncemented, primary total hip arthroplasty: 10-year results in 155 patients using two stem shapes and modular necks. *Acta Orthop.* 2010;81(1):126-33.
4. Novoa-Parra CD, Pelayo-de Tomás JM, Gómez-Aparicio S, López-Trabucco RE, Morales-Suárez-Varela M, Rodrigo-Pérez JL. Primary total hip arthroplasty with fourth-generation ceramic bearings: Clinical and survival results with a minimum follow-up of 5 years. *Rev Esp Cir Ortop Traumatol.* 2019;63(2):110-21. doi: 10.1016/j.recote.2018.07.012.
5. Fitch DA, Ancarani C, Bordini B. Long-term survivorship and complication rate comparison of a cementless modular stem and cementless fixed neck stems for primary total hip replacement. *Int Orthop.* 2015;39(9):1827-32. doi: 10.1007/s00264-015-2894-4.
6. Lex JR, Welch MD, See A, Edwards TC, Stavropoulos NA, Babis GC. Systematic review of primary total hip arthroplasty using titanium-titanium modular-neck prostheses: the true risk of revision. *HIP Int.* 2021;31(3):295-303. doi: 10.1177/1120700020916870.
7. Zajc J, Molić A, Fokter SK. Dual Modular Titanium Alloy Femoral Stem Failure Mechanisms and Suggested Clinical Approaches. *Materials (Basel).* 2021;14(11):3078. doi: 10.3390/ma14113078.
8. Colas S, Allalou A, Poichotte A, Piriou P, Dray-Spira R, Zureik M. Exchangeable Femoral Neck (Dual-Modular) THA Prostheses Have Poorer Survivorship Than Other Designs: A Nationwide Cohort of 324,108 Patients. *Clin Orthop Relat Res.* 2017;475(8):2046-59. doi: 10.1007/s11999-017-5260-6.
9. Pour AE, Borden R, Murayama T, Groll-Brown M, Blaha JD. High Risk of Failure With Bimodular Femoral Components in THA. *Clin Orthop Relat Res.* 2016;474(1):146-53. doi: 10.1007/s11999-015-

- 4542-0.
10. Gofton WT, Illical EM, Feibel RJ, Kim PR, Beaulé PE. A Single-Center Experience With a Titanium Modular Neck Total Hip Arthroplasty. *J Arthroplasty*. 2017;32(8):2450-6. doi: 10.1016/j.arth.2017.03.025.
 11. Pelayo-de-Tomás JM, Rodrigo-Pérez JL, Novoa-Parra CD, Lizaur-Utrilla A, Morales-Suárez-Varela M, Blas-Dobón JA. Cementless modular neck stems: are they a safe option in primary total hip arthroplasty? *Eur J Orthop Surg Traumatol*. 2018;28(3):463-9. doi: 10.1007/s00590-017-2071-0.
 12. Kovač S, Mavčič B, Kotnik M, Levašič V, Sirše M, Fokter SK. What factors are associated with neck fracture in one commonly used bimodular THA design? A multicenter, nationwide study in Slovenia. *Clin Orthop Relat Res*. 2019;477(6):1324-32. doi: 10.1097/CORR.0000000000000646.
 13. Vanbiervliet J, Somers JFA. Excellent mid-term results of a new polished tapered modular cemented stem: a study of 113 hip replacements with minimum 5-year follow-up. *Hip Int*. 2017;27(5):455-459. doi: 10.5301/hipint.5000486.
 14. Krishnan H, Krishnan SP, Blunn G, Skinner JA, Hart AJ. Modular neck femoral stems. *Bone Jt J*. 2013;95 B(8):1011-21. doi: 10.1302/0301-620X.95B8.
 15. Lee EW, Kim HT. Early fatigue failures of cemented, forged, cobalt-chromium femoral stems at the neck-shoulder junction. *J Arthroplasty*. 2001;16(2):236-8. doi:10.1054/arth.2001.20542.
 16. Botti TP, Gent J, Martell JM, Manning DW. Trunion fracture of a fully porous-coated femoral stem: Case report. *J Arthroplasty*. 2005;20(7):943-5. doi: 10.1016/j.arth.2005.06.013.
 17. Vučajnk I, Fokter KS. Modular Femoral Neck Fracture After Primary Total Hip Arthroplasty. *J Arthroplasty*. 2012;28(1):196.e7-196.e9.
 18. Ellman MB, Levine BR. Fracture of the Modular Femoral Neck Component in Total Hip Arthroplasty. *J Arthroplasty*. 2013;28(1):196.e1-196.e5. doi: 10.1016/j.arth.2011.05.024.
 19. Sotereanos NG, Sauber TJ, Tupis TT. Modular Femoral Neck Fracture After Primary Total Hip Arthroplasty. *J Arthroplasty*. 2013;28(1):196.e7-196.e9. doi: 10.1016/j.arth.2012.03.050.
 20. Mencièrè ML, Amouyel T, Taviaux J, Bayle M, Laterza C, Mertl P. Fracture of the cobalt-chromium modular femoral neck component in total hip arthroplasty. *Orthop Traumatol Surg Res*. 2014;100(5):565-8. doi: 10.1016/j.otsr.2014.03.027.
 21. Baratz MD, Abdeen A. Fracture of a tapered femoral neck after total hip arthroplasty: A case report. *JBJS Case Connect*. 2014;4(1):1-4. doi: 10.2106/JBJS.CC.M.00155.
 22. Hernandez A, Gargallo-Margarit A, Barro V, Gallardo-Calero I, Sallent A. Fracture of the Modular Neck in Total Hip Arthroplasty. *Case Rep Orthop*. 2015;2015:591509. doi: 10.1155/2015/591509.
 23. Trieb K, Stadler N. A New Case of Fracture of a Modular Femoral Neck Device After a Total Hip Arthroplasty. *Open Orthop J*. 2015;9(1):126-8.
 24. Fokter SK, Rudolf R, Moličnik A. Titanium alloy femoral neck fracture-clinical and metallurgical analysis in 6 cases. *Acta Orthop*. 2016;87(2):197-202. doi: 10.3109/17453674.2015.1047289.
 25. Fokter SK, Moličnik A, Kavalar R, Pelicon P, Rudolf R, Gubeljak N. Why do some titanium-alloy total hip arthroplasty modular necks fail? *J Mech Behav Biomed Mater*. 2017;6:107-14. doi: 10.1016/j.jmbbm.2016.12.012.
 26. Ceretti M, Falez F. Modular titanium alloy neck failure in total hip replacement: analysis of a relapse case. *SICOT J*. 2016;2:20. doi: 10.1051/sicotj/2016009.
 27. Skendzel JG, Blaha JD, Urquhart AG. Total Hip Arthroplasty Modular Neck Failure. *J Arthroplasty*. 2011;26(2):338.e1-338.e4. doi:10.1016/j.arth.2010.03.011.
 28. Uchiyama K, Yamamoto T, Moriya M, Fukushima K, Minegishi Y, Takahira N, et al. Early fracture of the modular neck of a MODULUS femoral stem. *Arthroplast Today*. 2017;3(2):93-8. doi: 10.1016/j.artd.2016.09.004.
 29. Murena L, Maritan G, Concina C, Scamacca V, Ratti C, Canton G. Fracture of cobalt-chrome modular neck in total hip arthroplasty. *Acta Biomed*. 2019;90:187-91. doi: 10.23750/abm.v90i12-S.8941.
 30. Regis D, Christodoulidis A, Magnan B, Sandri A. Late fracture of an old-generation modular neck

- in a titanium alloy femoral stem of a cementless total hip arthroplasty. *J Clin Orthop Trauma*. 2019;10(5):1008-11. doi: 10.1016/j.jcot.2018.06.008.
31. Lanzutti A, Andreatta F, Rossi L, Di Benedetto P, Causero A, Magnan M, et al. Corrosion fatigue failure of a high carbon CoCrMo modular hip prosthesis: Failure analysis and electrochemical study. *Eng Fail Anal*. 2019;105:856-68. doi: 10.1016/j.engfailanal.2019.07.044.
 32. Fokter SK, Gubelj N, Predan J, Sevšek J, Zajc J, Krajnc Z. Bilateral neck fracture in bimodular femoral stem after primary total hip arthroplasty: a case report. *BMC Musculoskelet Disord*. 2021;22(1):1-7. doi: 10.1186/s12891-021-04210-y.
 33. Wilson DAJ, Dunbar MJ, Amirault JD, Farhat Z. Early failure of a modular femoral neck total hip arthroplasty component: A case report. *J Bone Jt Surg*. 2010;92(6):1514-7. doi: 10.2106/JBJS.I.01107.
 34. Wright G, Sporer S, Urban R, Jacobs J. Fracture of a modular femoral neck after total hip arthroplasty: A case report. *J Bone Jt Surg*. 2010;92(6):1518-21. doi: 10.2106/JBJS.I.01033.
 35. Atwood SA, Patten EW, Bozic KJ, Pruitt LA, Ries MD. Corrosion-induced fracture of a double-modular hip prosthesis: A case report. *J Bone Jt Surg*. 2010;92(6):1522-5. doi: :10.2106/JBJS.I.00980.
 36. Dangles CJ, Altstetter CJ. Failure of the modular neck in a total hip arthroplasty. *J Arthroplasty*. 2010;25(7):1169.e5-1169.e7. doi: 10.1016/j.arth.2009.07.015.
 37. Kohler S, Ratayski H, Zacher J. Implantatbedingte brüche des schenkelhals-konusadapters einer modularen kurzschaft-hüftendoprothese - Patientenmanagement und OP-technik. *Z Orthop Unfall*. 2011;149(2):185-90.
 38. Paliwal M, Gordon Allan D, Filip P. Failure analysis of three uncemented titanium-alloy modular total hip stems. *Eng Fail Anal*. 2010;17(5):1230-8.
 39. Gilbert JL, Mali S, Urban RM, Silverton CD, Jacobs JJ. In vivo oxide-induced stress corrosion cracking of Ti-6Al-4V in a neck-stem modular taper: Emergent behavior in a new mechanism of in vivo corrosion. *J Biomed Mater Res - Part B Appl Biomater*. 2012;100 B(2):584-94.
 40. Pourzal R, Lundberg HJ, Hall DJ, Jacobs JJ. What Factors Drive Taper Corrosion? *J Arthroplasty*. 2018;33(9):2707-2711. doi: 10.1016/j.arth.2018.03.055.
 41. Aspenberg P, Kolmert L, Persson L, Onnerfält R. Fracture of hip prostheses due to inadequate welding. *Acta Orthop Scand*. 1987;58(5):479-82. doi: 10.3109/17453678709146382.

READY - MADE
CITATION

Panagopoulos A, Solou K, Tatani I, Tatarakis D, Megaspis P. Fracture of femoral neck in modular total hip arthroplasty: Report of 3 cases and review of the literature. *Acta Orthop Trauma Hell* 2022; 73(4): 347-354.