

# Sciwora: Diagnosis and treatment

## A systematic review

Stefania Nikolaou, MD

2<sup>nd</sup> Department of Orthopaedic Surgery, KAT Hospital

[stefsurg46@gmail.com](mailto:stefsurg46@gmail.com)

030-2110158251

### ABSTRACT

SCIWORA (Spinal Cord Injury Without overt Radiological Abnormality) is a term first used by Loyd, back in 1907, even though it became more known in 1982 by Pang. The initial term described a condition where signs of myelopathy were not accompanied by traumatic findings on plain radiographs or on computed tomography and it was mostly believed to be a medical condition seen in children. Throughout the years it has been shown that SCIWORA is not only seen in children but it is also seen in adults. Introducing MRI to the diagnostic algorithm caused controversy about what should be defined as SCIWORA, but it also added to the comprehension of the pathophysiology of SCIWORA. The aim of this study was to investigate the current trends in diagnosis and possible treatments of SCIWORA. The reviewed articles were obtained by using the online Pubmed and Google scholar databases and by following the PRISMA guidelines. While there is no consensus on a protocol, the current management protocols include immediate bracing, avoiding the administration of corticosteroids and performing an MRI as the main diagnostic imaging. The decision for surgical intervention seems to be taken based on the MRI findings and the skills of the practitioner.

**Key Words:** Sciwora, Sciworet

#### Introduction

SCIWORA stands for spinal cord injury without overt radiologic abnormality. Pang defined it as a spinal cord injury leading to myelopathy without any findings on radiographs or on computed tomography. At first it was believed to be more frequent in children but through the years it has been found that specific adult groups are also predisposed to SCIWORA. [1, 2, 3, 4]

The symptoms consist of transient numbness to even quadriplegia.[5] Most of times symptoms appear as

soon as the injury occurs but cases of late onset SCIWORA have also been reported in the literature.[6,7]

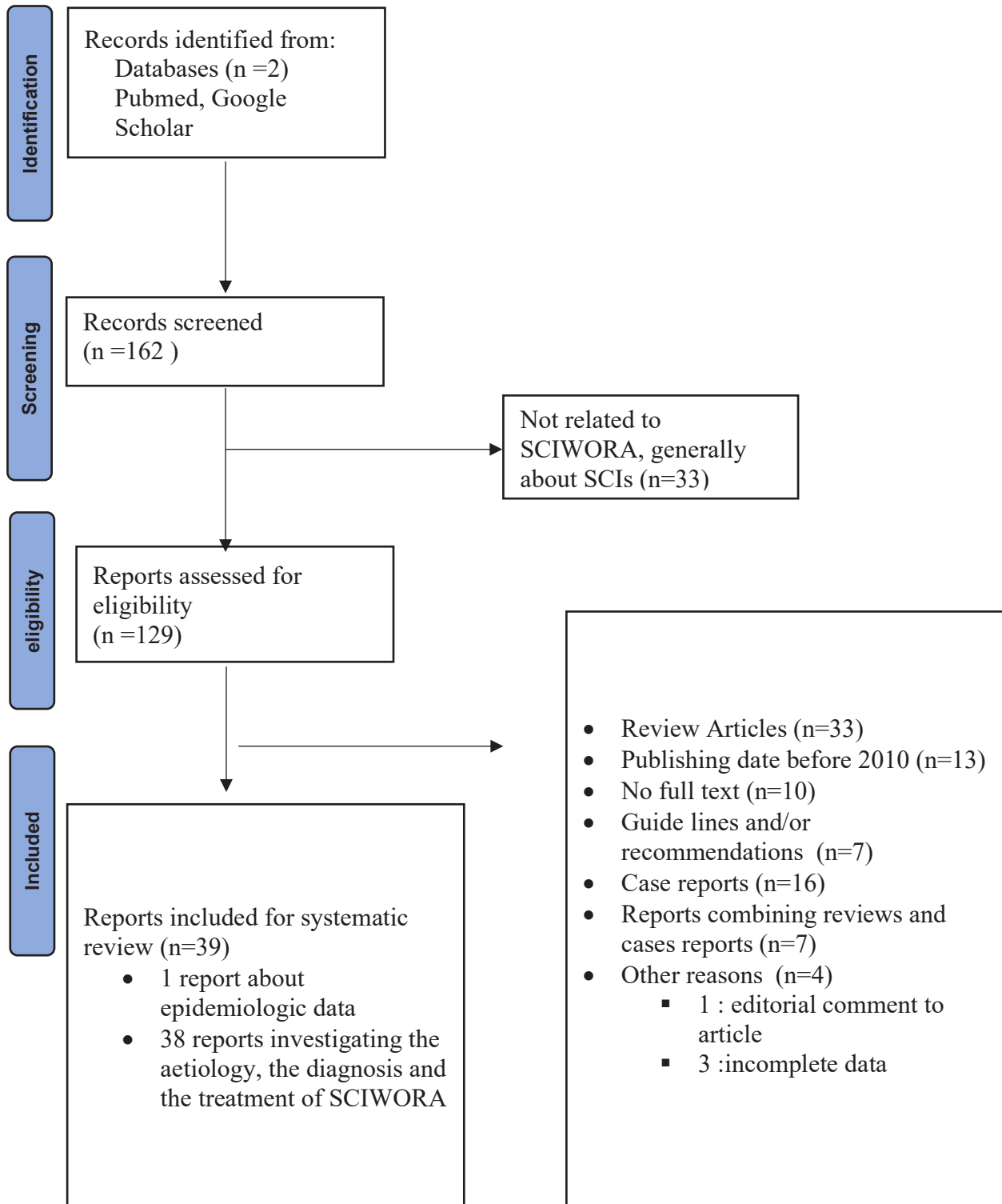
In the past decades, plain radiography and computed tomography had been the main diagnostic tools for spinal cord injuries. Currently MRI is the gold standard in the imaging of these injuries since it evaluates not only the bony structures but also the soft tissue structures as the ligaments, the discs and the spinal cord. [8] It has been stated that the degree of the damage at the soft tissue is proportional to the severity of SCIWORA.[9]

CORRESPONDING  
AUTHOR,  
GUARANTOR

Elias S. Vasiliadis

Assistant Professor of Orthopaedic Surgery 2132086209

[eliasvasiliadis@yahoo.gr](mailto:eliasvasiliadis@yahoo.gr) 3rd Department of Orthopaedic Surgery NKUA, KAT Hospital



Even though there are no official guidelines for SCIWORA, the majority of practitioners seem to agree on immediate immobilization of the cervical spine. [10,11,12,13] Administration of corticosteroids (NASCIS protocols) has been debated and even rejected by some. [9, ] Surgical treatment has also been discussed as a possibility in patients with deteriorating neurological status [22].

The purpose of this study was to investigate the current diagnostic and treatment protocols of SCIWORA and provide the bigger picture on its controversy. For this reason, a review of the current literature was conducted by using the online Pubmed and Google Scholar databases and following the PRISMA guidelines. Article titles were searched by using the following keywords: "SCIWORA" and "SCIWORET". Studies published after 2010, retrospective studies, prospective studies and clinical studies on surgical treatment were included in the review. On the contrary, studies published in other than English language, review articles, case reports, studies published before 2010, guidelines and/or recommendations, articles combining a review and a case report and articles about spinal cord injuries in general were excluded from this review. Primary search results included 162 articles. After screening of titles and abstracts, 33 articles were excluded since they were generally about Spinal Cord Injuries and not related to SCIWORA, leaving 129 articles for screening. From the remaining 129 studies, 90 were rejected for various reasons (Table 1). Finally, 43 studies were included in this review.

## Discussion

SCIWORA is defined as spinal cord injury without overt radiological abnormality. The definition's original description included negative plain radiographs and/or computed tomography. [6] Throughout the years magnetic resonance imaging became an integral diagnostic tool for spinal cord injuries helping at understanding the pathophysiology of the injury but also causing a controversy on which cases should be really diagnosed as SCIWORA. [1,2,2,5,3] Since MRI has been established as the basic imaging method for diagnosing SCIWORA, a number of new terms have been suggested such as SCIWOCTET (Spinal Cord Injury Without Computed Tomography Evidence of Trau-

ma) [15,24], ASCIWORA (Adult SCIWORA) [16,4], SCIWORET (Spinal Cord Injury Without Radiographic Evidence of Trauma) [13,17], Real SCIWORA [5] and SCIWONA (Spinal Cord Injury Without Neurological Abnormality) [6].

## 1. Etiology

SCIWORA is a traumatic condition of the spinal cord where there is no compromise of the bony structures of the spine. There is no evidence of fractures or subluxations on radiographs and/or computed tomography. SCIWORA's etiology seems to differentiate according to patients' age group. [1,3,7] As a matter of fact, patients with SCIWORA can be divided in two age groups, children and infants younger than 8 years old and adults older than 60 years old. [1]

Children are anatomically predisposed to SCIWORA due to a series of reasons. Firstly the size of their head is relatively larger and heavier comparatively to the size of the adult head resulting in movements that shift the maximum force to the C2-C3 spinal level. [8] Furthermore, it has been shown that the pediatric spine is quite elastic in contrast with the spinal cord: the spine can be stretched by 2" while the cord can only be stretched by 0.25" before it shows signs of trauma. [9] This is due to the horizontal and shallow facet joints, the stretchable ligaments and the fact that the uncinated processes are still absent [22]. This is also supported by cadaver studies which revealed that flexion injuries to the pediatric spine were capable of causing subluxation resulting to myelopathy, but no damage at the bony and ligamentous structures. [26] Makino et al, reviewed postmortem multidetector computer tomography scans (MDCT) which were performed within the forensic investigations. Before the autopsy, an MDCT was performed and the scans were interpreted by radiologists experienced in forensic radiology. The study came to the conclusion that MDCT is not capable of replacing autopsy for diagnosing SCIWORA. In addition, children younger than 8 years old have delicate blood vessels supplying the spinal cord, making them even more prone to such injuries [22].

Adults older than 60 constitute the second high risk group for suffering SCIWORA. [1] Adult patients diagnosed with SCIWORA have been reported to have a number of anatomic changes on their spine. The re-

duced diameter of the cervical spinal canal [10] and the degenerative changes of the spine that are expected in this age group[11,3] are the main aggravating factors. Additionally MRI proved that 76% of patients with SCIWORA had herniated discs. [10,15] Makino's study confirmed the existence of disc herniations and disc injuries in these patients.[12]

## 2. Mechanism of injury

A number of different types of injuries can cause SCIWORA, and the most common are motor vehicle accidents and falls.[ 13,20]. Falls from heights is the next most common cause. Less often, sports related injuries can cause SCIWORA. Not so common causes include being stricken by a moving object, penetrating injuries and assaults. [14 ]

Regardless of the cause of injury, the underlying mechanism of injury is usually hyperextension movement of the neck.[5] The exact way that hyperextension causes SCIWORA is still being analyzed but it is suggested that hyperextension leads to a temporary occlusion of the vertebral arteries which is followed by a spontaneous return of the vertebrae to their original position, resulting to ischemia.[5] Neonates are highly predisposed to this kind of injury due to the peculiarities of the anatomy of their atlanto-occipital articulation. Hyperextension can also force the interlaminar ligaments forward into the spinal canal, narrowing it down by even half of its diameter.[7] Apart from hyperextension, mechanisms of injury also include flexion, distraction and ischemia. Distraction injuries are mostly seen in children especially younger than 5 years of age.

## 3. Symptoms of SCIWORA

As it is described, SCIWORA is a traumatic condition leading myelopathy where imaging gives little to no information. The starting point of the diagnostic algorithm is the clinical presentation. Sciwora has a large range of symptoms which may vary from a transitional numbness to a complete quadriplegia. Neurological deficits as hand and arm numbness,[ 6,15] weakness of the lower extremities, inability to move[ 33] and even complete paraplegia has been reported.[ 7] The neurological deficits may be transient or permanent. Transient symptoms seem to resolve within 72 hours. [18]

Some researchers have tried to classify the neurological status into categories according to the motor and sensory findings[8]. Diagnosis of SCIWORA in very young children may be challenging because the involuntary reflex movements of the lower limbs mimic the normal movements.[22] In case of upper thoracic injuries the red flag symptoms may be pulmonary complications because of the impaired function of respiratory muscles. [22] Other symptoms that have been reported are neck pain or tenderness, altered mental status and torticollis.[23]

The onset of the symptoms may also differ. Some patients have stated that they only experienced the symptoms at the exact moment of the injury.[5] It has been shown that the time period between the injury and the appearance of the symptoms can range from 30 minutes to even 4 days.[7,29] This delayed onset of symptoms seems to have no obvious correlation with the mechanism of injury or with the age of the patient. [29] This phenomenon is called late onset SCIWORA. Some of the patients who were diagnosed as late onset SCIWORA cases reported that they actually had some transient neurological symptoms at the time of the injury, such as lightning sensation, numbness or paresthesia.5 There was no incident of a second trauma between the time of injury and the final development of the symptoms. [ 29] However, it is not to be missed that some of the patients who were deemed late onset SCIWORA cases might had symptoms at the time of the injury which were missed in the initial examination.[7]

Recurrent SCIWORA is another phenomenon described in the literature. It is described as a second injury to the spinal cord after the initial injury in the following 3 days to 10 weeks [6]. It is believed that the post traumatic period is a vulnerable period for the spine and according to the reported cases, the second injury is always more severe than the first one.[6,7]

## 4. Diagnosis of SCIWORA

Diagnosing SCIWORA begins with the arrival of the patient at the emergency room, containing a carefully taken history and clinical evaluation.[6] The majority of the clinical practitioners use the ASIA score to categorize the patient's status according to the neurological deficits.[16] The imaging evaluation used to consist of radiographs of the cervical spine and even an open

mouth view of the odontoid.[6] It is obvious that in the era of using only plain radiographs the diagnosis of SCIWORA was done by exclusion. A number of practitioners have discussed the use of dynamic radiographs. Plain radiographs performed with the cervical spine in flexion and extension can indicate the stability of the spine.[31] The timing of their performance has also been discussed as in the acute period of the injury the muscle spasm can change the results, concluding to performing the dynamic radiographs around a week after the injury. [6, 36] However it is not a common tactic anymore as researchers have concluded that the existing instability can cause even more damage to the already injured spinal cord.[17,36] Computed tomography has been used in order to exclude fractures and dislocations as it is the most precise examination when it comes to diagnosing bony abnormalities.[5] MDCT has even been suggested to be part of the investigation of traumatic deaths as it has been shown that there is an interesting correlation between post mortem results and autopsy findings.[28]

In the 80s, somatosensory evoked potentials (SSEPs) were performed usually within 24 hours of patient's admission.[6] However it was soon considered to be a special test rather than a routine test for diagnosing SCIWORA.[7] SSEPs' possible uses could be the detection of subtle posterior column dysfunction, evaluating patients who are comatose or head injured and it could also provide a baseline MRI examination for comparison.[12]

MRI was definitely a breakthrough for diagnosing SCIWORA as it can show the actual damage of the spinal cord when plain radiographs and sometimes even CTs seem normal.[18] In the literature, it is stated that occult instability in SCIWORA was not proven until MRI was added on the tests that were performed on patients.[7] MRI is argued to be the only imaging option when it comes to imaging the damages of the spinal cord.[23] MRI abnormalities can be categorized as extra neural and neural.[1,7] Extra neural abnormalities consist of soft tissue damage as disc herniation, intradiscal hemorrhages and ligamentous damages. [7] On the other hand, neural abnormalities shown on MRI contain disruption of the spinal cord, cord hemorrhage and edema.[7] MRI can also be prognostic of the outcome.[17,25] Most practitioners agree that MRI

findings in SCIs can be classified to four patterns; normal MRI, single level edema, multilevel edema and a mix of hemorrhage and edema.[20] Following that, attempts were made to find a correlation between the MRI findings and the clinical presentation in order for MRI to be prognostic and not only diagnostic.[33,12] However MRI is not diagnostic in all cases since it has been documented that patients with persistent neurologic deficits may present with normal MRI.[5] The timing of performing the MRI seems to be related with the findings as it has been shown that sometimes early performed MRIs do not always correlate with the neurological outcome.[8] According to some authors, the best time for performing an MRI is 24-72 hours after the injury.[ 9] The initial MRI can sometimes show no abnormalities so it has been suggested to perform another MRI in the following 24 and 72 hours.[8] A study by Ouchida et al, compared the MRI results performed within 48 hours and two weeks after the injury. The practitioners concluded that the delayed MRI reflected the severity of the neurological deficits much more precisely than the acutely performed MRI. The MRI performed right after the injury could not show the increased signal intensity or the prevertebral hyperintensity as they really were.[19] A quite controversial subject is the advanced MRI sequences such as the SWI and the DTI. These are more accurate on imaging hemorrhage but unfortunately they are very sensitive to breathing motion and to artifacts caused by bones.[ 20] Specifically, DWI has been suggested as an imaging way to evaluate the integrity of white matter tracts in spinal cord due to its ability to depict the microscopic motion of water protons. In summary DWI could be used in order to evaluate the severity of the injury.[20] A few years back, Zhang and Xia suggested that during the surgical intervention of corpectomy and fusion discs that are suspicious for injuring the cord could be injected with iohexol, under C-arm monitoring, in order to check the integrity of the disc. The patients enrolled in the study suffered neurological deficits such as weakness and numbness in their upper and lower limbs. The MRI findings consisted of swollen soft tissue and disc degeneration. The patients underwent anterior cervical surgery. During the surgery the suspected discs were injected. As a result the leakage revealed the degenerated discs. These discs would be removed

and replaced with a cage filled with bone graft.[21]

### 5. Treatment

There is no universal consensus about the treatment options of SCIWORA. There is an ongoing controversy about whether and when to operate, while the administration of corticosteroids is most likely to be abandoned by the majority of the practitioners.

The treatment of SCIWORA and every spinal cord injury in general begins at the sight of the accident with the placement of a hard collar. Immediate immobilization with a hard collar is the common tactic as well as the use of a fracture board if the thoracic spine is compromised too.[6] The immobilization is continued throughout the management of the patient at the emergency room. In fact, it is stated that the collar should only be removed once the patient is sedated and intubated and the immobilization is then accomplished with sand bags keeping the neck in a neutral position.[34]

The period of immobilization and whether the treatment should remain conservative are the main reasons for debate. Before 1985 a Philadelphia collar was placed for 8 weeks and after it was removed the stability of the spine was checked by dynamic radiographs.[6] After 1985 a Guildford brace was worn for 12 weeks. Additionally, sports were strictly prohibited for 3 months.7 Others suggest avoiding high risk activities for months in order to decrease the possibility of a new injury.[5] Another suggestions was immobilization by halter traction and minimal weight for 3 weeks.2

Along with immobilization, the administration of corticosteroids is being discussed extensively. Practitioners seem to be divided in those who have rejected the NASCIS protocols and those who still administrate corticosteroids combined or not with surgical intervention.[1] It is stated that corticosteroids should be administrated to patients with persistent neurologic deficits.[36] Administrating corticosteroids can lead to a number of complications such as infections of the pulmonary system and gastrointestinal bleeding. However, if administrated in the right dosage, corticosteroids can provide an improvement. This applies in cases that the patient needs to be transferred to another medical unit before a possible surgical intervention.

Recently, it has been suggested that stem cell therapy could be effective in pseudo complete SCIWORA

injuries.[22] This means that patients who have axons that are non-functional but they still react to stimulus can benefit from both stem cell therapy and supportive cell therapy. Regeneration of the axons could be supported by the transplantation of neurotrophic factors. These have an anti inflammatory effect over the axons and additionally promote their regeneration.

The decision for surgical intervention in SCIWORA cases is not an easy decision to make since the level of instability is not always obvious. Furthermore surgical intervention always comes with all the possible complications of surgery, including the second hit syndrome. There is no guideline in the literature for when to operate and when to remain conservative so the decision is upon the physician. It seems that pediatric patients have a good outcome with conservative treatment while adult patients usually respond better to surgical intervention, probably due to the increased disc injury and the bulging of the ligamentum flavum. [13]

Researchers have categorized the SCIWORA injuries in four types. Type I means that there is no detectable MRI findings, type IIa means that there are intraneural abnormalities, type IIb means that there are extra neural abnormalities and type IIc means that are both intraneural and extra neural abnormalities are identified. Some researchers decide whether to operate or not according to what type of SCIWORA the patient suffers from. Type IIc which combines both intraneural and extra neural abnormalities is usually treated surgically.[28] In general, surgery is indicated for unstable injuries, dislocations, progressive deformities and for cases where decompression is needed.

A quite commonly followed operative treatment is expansive laminoplasty which can be combined with fusion if the spine is kyphotic or has degenerative spondylolisthesis.[35] Mazaki et al, studied the neurological status as well as the complications of patients, of which some were treated conservatively and some were operated.[14] The practitioners concluded that the group of patients that underwent laminoplasty did not show any significant improvement in paralysis. However, the operated group seemed to have high rates of complications, especially of the urinary and respiratory system. Another operative option is anterior discectomy with

interbody fusion using a cervical cage.[23] This surgical option is described as a common technique in spinal cord injuries but it is only recently applied on SCIWORA cases. This procedure begins with an anterior approach, a discectomy and decompression followed by the positioning of the cervical cage which is usually filled with cancellous autograft. In Huang's study, the outcome was rather positive, improving by one level on the Frankel scale and encountering no postoperative complications.[37] Alongside with laminectomy a durotomy and duroplasty has also been described in the literature.16 According to Zhu's study, durotomy can contribute to the decompression of the spinal cord and improve the neurological status as a result. As he describes, the patients underwent posterior laminectomy and durotomy. The extent of the durotomy was decided upon the segment with edema. The procedure included removal of the hematoma, rinsing with saline and finally suturing the dura. The results of the follow up were rather positive as the practitioners reported that even some patients with spinal cord hemorrhage or contusion marked improvement after surgery. This could mean that early decompression plays some role on the neurological improvement.

Another critical question to be answered is when to operate. The timing of the operation is very important for the neurological outcome. A recent study came to the conclusion that the optimal timing of operation is 3 to 7 days after the injury.[24]


Apart from the surgical procedures that aim to immediate decompress the cord there are also other procedures that are done afterwards in order to correct deformities. It is known that pediatric patients that

suffer from SCIWORA develop neuromuscular scoliosis. These long scoliotic curves that are sometimes combined with pelvic obliquity should be treated to improve pelvic balance and hip containment.[25] The followed technique is using pedicle screws.

### 6. Prognosis

It has been stated that the initial neurologic status is probably the most important prognostic factor. [32] This means that MRI can provide prognostic information according to the signal changes and the area of extension.[1] With further investigation, it has been shown that age over 45 years, the presence of degenerative changes of the spine and severe initial neurological deficit, are factors that contribute to poor outcome. [1] On the other hand, cord edema and age under 45 years seem to be connected with better prognosis.[13] Additionally, the time of surgical treatment is connected to the outcome as it has been shown that the most ideal time to operate is 3-7 days after the injury.[38]

### Conclusion

SCIWORA is a rather controversial injury. Throughout the years, researchers have proposed a series of other possible acronyms to be more precise with the diagnosis and findings of SCIWORA. There is not yet a consensus for the treatment, although there have been some studies supporting surgical treatment against conservative. The administration of corticosteroids tends to be abandoned by most practitioners even though some still use them on specific cases. Due to the rarity of the condition there are still many questions that need to be answered in order to have the best possible outcome for patients diagnosed with SCIWORA. 

## REFERENCES

- 1 Como, J. J., Samia, H., Nemunaitis, G. A., Jain, V., Anderson, J. S., Malangoni, M. A., & Claridge, J. A. (2012). The misapplication of the term spinal cord injury without radiographic abnormality (SCIWORA) in adults. *Journal of Trauma and Acute Care Surgery*, 73(5), 1261–1266. <https://doi.org/10.1097/ta.0b013e318265cd8c>
- 2 Zhu, F., Yao, S., Ren, Z., Telemacque, D., Qu, Y., Chen, K., Yang, F., Zeng, L., & Guo, X. (2019). Early durotomy with Duroplasty for severe adult spinal cord injury without radiographic abnormality: A novel concept and method of surgical decompression. *European Spine Journal*, 28(10), 2275–2282. <https://doi.org/10.1007/s00586-019-06091-1>
- 3 Neva, M. H., Roeder, C. P., Felder, U., Kiener, B., Meier, W., Perler, M., & Heini, P. (2011). Neurological outcome, working capacity and prognostic factors of patients with SCIWORA. *Spinal Cord*, 50(1), 78–80. <https://doi.org/10.1038/sc.2011.100>
- 4 Dreizin, D., Kim, W., Kim, J. S., Boscak, A. R., Bodanapally, U. K., Munera, F., & Stein, D. M. (2015). Will the real Sciwora Please stand up? exploring clinicoradiologic mismatch in closed spinal cord injuries. *American Journal of Roentgenology*, 205(4), 853–860. <https://doi.org/10.2214/ajr.14.13374>
- 5 Freigang, V., Butz, K., Seebauer, C. T., Karnosky, J., Lang, S., Alt, V., & Baumann, F. (2021). Management and mid-term outcome after “real sciwora” in children and adolescents. *Global Spine Journal*, 219256822097913. <https://doi.org/10.1177/2192568220979131>
- 6 Mahajan, P., Jaffe, D. M., Olsen, C. S., Leonard, J. R., Nigrovic, L. E., Rogers, A. J., Kuppermann, N., & Leonard, J. C. (2013). Spinal cord injury without radiologic abnormality in children imaged with magnetic resonance imaging. *Journal of Trauma and Acute Care Surgery*, 75(5), 843–847. <https://doi.org/10.1097/ta.0b013e3182a74abd>
- 7 Bazán, P. L., Borri, A. E., & Medina, M. (n.d.). *Predictors in adult sciwora*. Coluna/Columna. Retrieved June 5, 2022, from [http://old.scielo.br/scielo.php?pid=S1808-18512013000400014&script=sci\\_arttext&tlng=en](http://old.scielo.br/scielo.php?pid=S1808-18512013000400014&script=sci_arttext&tlng=en)
- 8 Basu, S. (2012). Spinal injuries in children. *Frontiers in Neurology*, 3. <https://doi.org/10.3389/fneur.2012.00096>
- 9 Rolfe, K., Beck, A., Kovach, T., Mayeda, B., & Liu, C. (2019). Non-locality and the misdiagnosis of spinal cord injury without radiographic abnormality: Proof of concept. *Spinal Cord Series and Cases*, 5(1). <https://doi.org/10.1038/s41394-019-0148-1>
- 10 Jiang, X., Chen, D., Lou, Y., & Li, Z. (2016). Kinematic analysis of cervical spine canal diameter and its association with grade of degeneration. *European Spine Journal*, 25(7), 2166–2172. <https://doi.org/10.1007/s00586-016-4624-z>
- 11 Boese, C. K., Müller, D., Bröer, R., Eysel, P., Krischek, B., Lehmann, H. C., & Lechler, P. (2016). Spinal Cord Injury without radiographic abnormality (SCIWORA) in adults: MRI type predicts early neurologic outcome. *Spinal Cord*, 54(10), 878–883. <https://doi.org/10.1038/sc.2016.13>
- 12 Makino, Y., Yokota, H., Hayakawa, M., Yajima, D., Inokuchi, G., Nakatani, E., & Iwase, H. (2014). Spinal cord injuries with normal postmortem CT findings: A pitfall of virtual autopsy for detecting traumatic death. *American Journal of Roentgenology*, 203(2), 240–244. <https://doi.org/10.2214/ajr.13.11775>
- 13 Knox, J. (2016). Epidemiology of spinal cord injury without radiographic abnormality in children: A nationwide perspective. *Journal of Children's Orthopaedics*, 10(3), 255–260. <https://doi.org/10.1007/s11832-016-0740-x>
- 14 Acharya, S., Sharma, V., Sharma, S., & Acharya, J. (n.d.). *Evaluation of clinical profile and effect of cervical spinal cord injuries with or without bony injuries*: Asian Journal of Medical Research. Retrieved June 5, 2022, from <https://aijournals.com/index.php/ajmr/article/view/462>
- 15 Pang, D., & Wilberger, J. E. (1982). Spinal Cord Injury without radiographic abnormalities in children. *Journal of Neurosurgery*, 57(1), 114–129. <https://doi.org/10.3171/jns.1982.57.1.0114>
- 16 Liao, C.-C., Lui, T.-N., Chen, L.-R., Chuang, C.-C., & Huang, Y.-C. (2005). Spinal cord injury without ra-



- diological abnormality in preschool-aged children: Correlation of magnetic resonance imaging findings with neurological outcomes. *Journal of Neurosurgery: Pediatrics*, 103(1), 17–23. <https://doi.org/10.3171/ped.2005.103.1.0017>
- 17 R, K. P. F. B. G. M. K. (n.d.). *Injury to the spinal cord without radiological abnormality (SCIWORA) in adults*. The Journal of bone and joint surgery. British volume. Retrieved June 5, 2022, from <https://pubmed.ncbi.nlm.nih.gov/11041597/>
- 18 Kriss, V. M., & Kriss, T. C. (1996). Sciwora (spinal cord injury without radiographic abnormality) in infants and children. *Clinical Pediatrics*, 35(3), 119–124. <https://doi.org/10.1177/000992289603500302>
- 19 Ouchida, J., Yukawa, Y., Ito, K., Katayama, Y., Matsumoto, T., Machino, M., Inoue, T., Tomita, K., & Kato, F. (2016). Delayed magnetic resonance imaging in patients with cervical spinal cord injury without radiographic abnormality. *Spine*, 41(16). <https://doi.org/10.1097/brs.0000000000001505>
- 20 Shen, H., Tang, Y., Huang, L., Yang, R., Wu, Y., Wang, P., Shi, Y., He, X., Liu, H., & Ye, J. (2006). Applications of diffusion-weighted MRI in thoracic spinal cord injury without radiographic abnormality. *International Orthopaedics*, 31(3), 375–383. <https://doi.org/10.1007/s00264-006-0175-y>
- 21 Zhang, J.-dong, & Xia, Q. (2015). Role of intraoperative disc contrast injection in determining the segment responsible for cervical spinal cord injury without radiographic abnormalities. *Orthopaedic Surgery*, 7(3), 239–243. <https://doi.org/10.1111/os.12197>
- 22 Shinozaki, M., Nagoshi, N., Nakamura, M., & Okano, H. (2021). Mechanisms of stem cell therapy in spinal cord injuries. *Cells*, 10(10), 2676. <https://doi.org/10.3390/cells10102676>
- 23 KZ;, H. S. L. Y. H. W. W. (n.d.). *Use of fidji cervical cage in the treatment of cervical spinal cord injury without radiographic abnormality*. BioMed research international. Retrieved June 29, 2022, from <https://pubmed.ncbi.nlm.nih.gov/23844369/>
- 24 Qi, C., Xia, H., Miao, D., Wang, X., & Li, Z. (2020). The influence of timing of surgery in the outcome of spinal cord injury without radiographic abnormality (SCIWORA). *Journal of Orthopaedic Surgery and Research*, 15(1). <https://doi.org/10.1186/s13018-020-01743-1>
- 25 Yalcin, N., Dede, O., Alanay, A., & Yazici, M. (2011). Surgical management of post-sciwora spinal deformities in children. *Journal of Children's Orthopaedics*, 5(1), 27–33. <https://doi.org/10.1007/s11832-010-0306-2>

READY - MADE  
CITATION

Nikolaou S. Sciwora: Diagnosis and treatment A systematic review. *Acta Orthop Trauma Hell* 2023; 74(1): 103-111.