

Adult Scoliosis: Therapeutic Approach and Spinal Pain Management

Maria Kontopanou¹, Ioannis S Benetos², Spyridon G. Pneumaticos³, Ioannis Vlamis⁴

¹Postgraduate Student of M.Sc. "Rehabilitation following Spinal Cord lesions. Spinal Pain Management", 3rd Department of Orthopaedic Surgery NKUA, KAT Hospital; Tel: 6981855371; email: maro_ul@windowslive.com

²MD; Academic fellow of Orthopaedic Surgery, 3rd Department of Orthopaedic Surgery NKUA, KAT Hospital; email: ioannisbenetos@yahoo.gr

³Professor of Orthopaedic Surgery, 3rd Department of Orthopaedic Surgery NKUA, KAT Hospital; email: spirospneumaticos@gmail.com

⁴MD; Assistant Professor of Orthopaedic Surgery, 3rd Department of Orthopaedic Surgery NKUA, KAT Hospital; email: jvlamis@med.uoa.gr

ABSTRACT

Advancing adult scoliosis may lead in deterioration of patients' overall health and progressive disability. It can be a quite complex disorder to manage; however, nowadays there are several conservative and surgical therapeutic approaches. The aim of this study was to review the current literature concerning the therapeutic management of patients with adult scoliosis and the management of spinal pain that the majority of these patients experience. The review of the current literature was carried out by using the online PubMed database and the following keywords: ("adult" [MeSH Terms] AND ("scoliosis" [MeSH Terms] AND ("pain" [MeSH Terms] AND ("conservative treatment" [MeSH Terms] AND ("spinal fusion" [MeSH Terms]). The primary search recovered 3.941 publications. In the initial screening of abstracts and titles, 3,902 articles were excluded because of either irrelevant titles or not matching content. From the remaining 39 studies, in which the full text was assessed, 12 were rejected due to particular reasons. Finally, 27 studies were included in this review. In conclusion, a variety of therapeutic approaches for adult scoliosis exist. The type of treatment depends on various factors and has to be personalized. The prevailing aspect is that patients with moderate scoliosis should seek conservative treatment first, as long as there isn't any serious deterioration in their symptoms and quality of life. Conservative management should be exhausted before any decision for surgery is taken.

Key Words: adult, scoliosis, pain, conservative treatment, spinal fusion

Introduction

Scoliosis is described as a three-dimensional malformation of the spine. The typical method to measure the deformation of the spinal curvatures is the Cobb

technique. A Cobb angle of ≥ 10 degrees clearly marks the presence of scoliosis [1, 2, 3]. Scoliosis can be classified into structural and non-structural or functional. Structural scoliosis is by far the most common type of

CORRESPONDING
AUTHOR,
GUARANTOR

Maria Kontopanou, Postgraduate Student, NKUA
Email: ds.evangelopoulos@gmail.com

scoliosis and it is characterized by a stiff lateral curvature of the spine that includes a component of rotation as well. The spinal deformation is permanent unless treated. The most common types of structural scoliosis are neuromuscular, congenital, adolescent idiopathic and degenerative or “de novo”. Non-structural is the type of scoliosis that involves a non-permanent lateral curvature of the spine without spinal rotation. Non-structural or functional scoliosis is caused mainly in response to an underlying painful condition as muscle spasms, osteoid osteoma of the spine or appendicitis in order for the patient to maintain an antalgic position. Another common cause of functional scoliosis is leg length discrepancy. If the patient bends forward or is lying down the curve is most likely to disappear. In addition, during a radiographic assessment the curve can be corrected with lateral bending to the opposite side. Treating the underlying cause corrects this type of scoliosis [4].

Adult scoliosis can stem from different causes and has two basic types: adolescent idiopathic scoliosis that keeps evolving during adulthood and degenerative or “de novo” scoliosis that affects adults without scoliosis history and often manifests after the fourth decade of life. The yearly increase of the scoliotic curve is 1.6 degrees for degenerative and 0.24 degrees for idiopathic scoliosis [11]. Degenerative scoliosis is a result of the degeneration of spinal components such as facet joints and discs that occurs with aging and usually affects the lumbar and thoracolumbar spine [4-7]. A sufficient number of studies mention the high incidence of scoliosis in the adult population. Indeed, in the elderly population from the age of 60 years and over the incidence may be as high as 68% [5, 7-13]. Neuromuscular scoliosis can be due to central or peripheral neurologic conditions that have an effect on the developing spinal column. It can also develop from conditions that affect muscle tissue like arthrogryposis, muscular dystrophy and Duchenne myopathy. All these conditions can lead to muscular imbalance and atrophy of the spinal muscles. Aging is a major cause of deterioration of this condition [14, 15].

There are several similar symptoms between the different types of adult scoliosis. The leading symptom is back pain that mainly derives from insufficiency and contractions of the spinal and postural muscles. In ad-

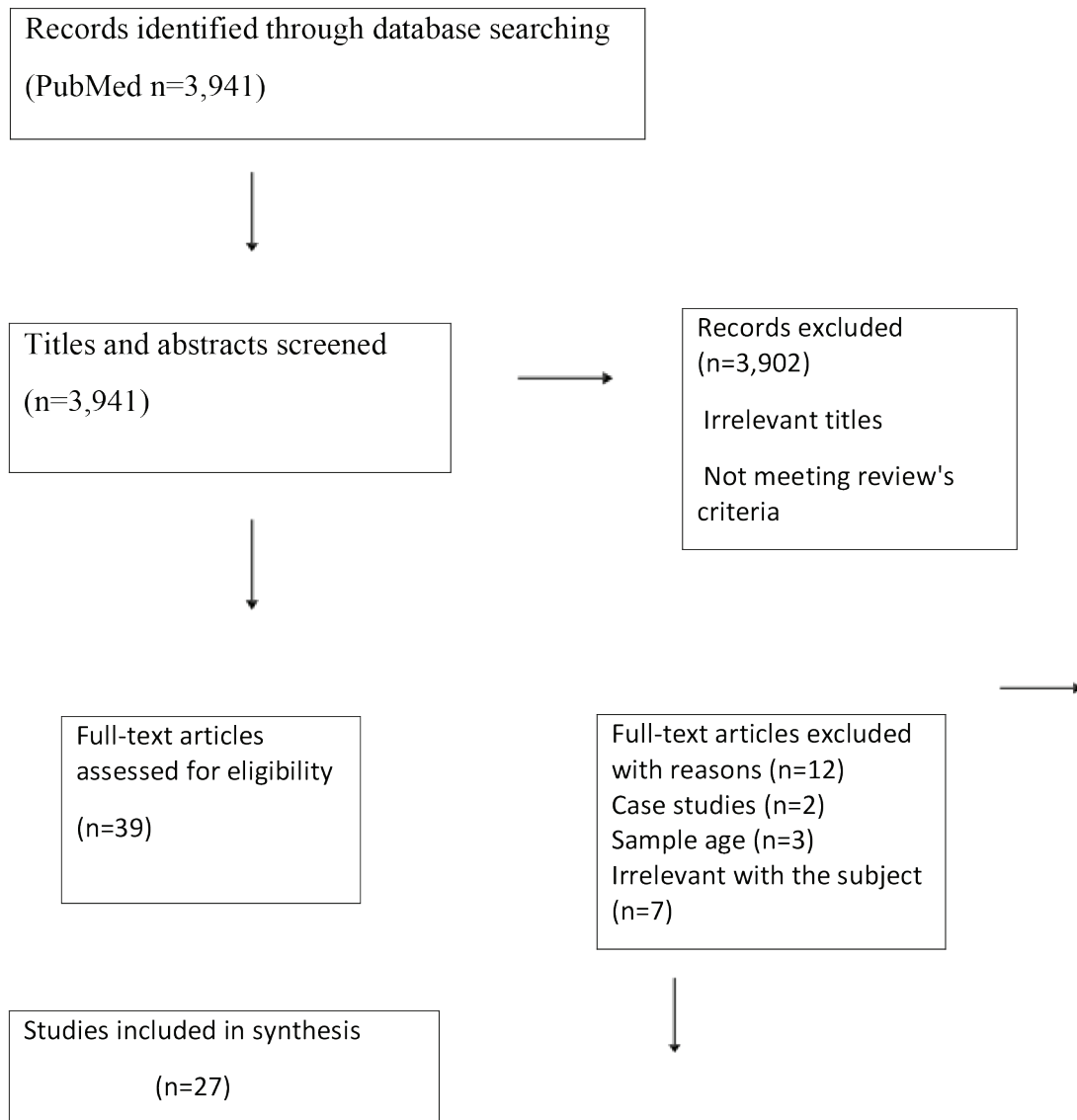
dition, back pain can derive from the lack of equilibrium in the frontal or sagittal plane and the subsequent degeneration of spinal components such as the articular facets and the intervertebral discs [1]. Another cause of back pain could be the lack of lumbar lordosis [3, 11]. Although it has been shown that pain is not directly related with the scoliotic curve’s magnitude and location, lumbar and thoracolumbar curves have increased risk to cause pain [3]. Patients with degenerative scoliosis experience back pain in a percentage of 40-90% [11]. Often, the pain can be detected along the side of the convexity [16]. Back pain is associated with lumbar radiculopathy in 47-78% of cases [1, 7, 16]. In addition, patients with adult scoliosis after the 6th decade of their life may also develop symptoms of spinal stenosis and myelopathy [4].

Treatment of adult scoliosis includes conservative and surgical methods of management. Pain management and improvement of physical ability and quality of life is always an important goal for any type of treatment. However, surgical treatment has different indications from conservative treatment. Stopping further development of the spinal deformity and restoring or avoiding feature neurologic defects are the main indications for surgical treatment [1]. Traditionally, patients with curves $\geq 45-50^\circ$ are in need of surgery, usually spinal fusion [2]. However, when there are no disabling symptoms the first choice is usually conservative treatment [5]. Conservative treatment typically consists of oral medications (non-steroidal anti-inflammatory drugs, opiates, amitriptyline, gabapentin, pregabalin), epidural injections, nerve blocks, physiotherapy, specific scoliosis and stabilization exercises and soft or rigid bracing [5, 6, 9, 17, 18, 19, 20].

The aim of this study was to review the current literature concerning the therapeutic management of patients with adult scoliosis and the management of spinal pain that the majority of these patients experience.

Discussion

A review of the current literature was carried out by using the online PubMed database and the following keywords: (“adult” [MeSH Terms] AND (“scoliosis” [MeSH Terms] AND (“pain” [MeSH Terms] AND (“conservative treatment” [MeSH Terms] AND (“spinal fusion” [MeSH Terms]. Inclusion criteria to the re-



(Table 1. Flowchart)

view were: studies from 2010 and on, review articles, systematic reviews, randomized controlled trials, prospective and retrospective studies, pilot and cohort studies related to the therapeutic approach of adult scoliosis and spinal pain management. Articles in other than English language were excluded. The primary search recovered 3,941 publications. In the initial screening of abstracts and titles, 3,902 articles were excluded because of irrelevant titles and not matching content. From the remaining 39 studies in which the

full text was assessed, 12 were rejected due to particular reasons. Finally, 27 studies were included in this review (Table 1).

Bracing

Bracing is a treatment modality that seems to be used more and more as it is a non-invasive and inexpensive method to treat scoliosis. However, this conservative option is more popular and preferred in adolescence and childhood. Even though, in a recent study, adult

patients suffering from idiopathic or degenerative lumbar scoliosis that were prescribed a custom-molded lumbar sacral orthosis (LSO) which had to be worn for at least 6 hours daily, showed a crucial deceleration of angular value ($p < 0.0001$) [6]. In another study, adults with scoliosis suffering from chronic non-specific low back pain related to loss or reduction of lumbar lordosis seemed to benefit from lumbar bracing [3]. Furthermore, according to a recent review study, soft or rigid spinal bracing (with wearing prescription varying from 2 to 23 hours per day) used as monotherapy or in conjunction with physical therapy, led to moderate or significant pain relief as well as function improvement in patients with adult scoliosis. However, observations concerning the Cobb angle were various; curve magnitude improved moderately or significantly or progressed slower or not at all. Despite that fact, there were also cases that bracing didn't seem to affect the curve's progression [7]. In another recent study, peak scoliosis brace was found to be beneficial in reducing pain in adults with idiopathic scoliosis. After a four-week period of using the brace for 2-4 hours per day, 75% of patients noted some improvement regarding worst pain and leg pain and 65% noted improvement in chronic low back pain; however, the results were not statistically significant [13].

Exercising

Adults suffering from scoliosis with no critically important neurological symptoms or perdition of quality of life could manage their condition to a great degree by following an appropriate exercising program. However, there are certain limitations because exercising is recommended mainly in patients with adult idiopathic scoliosis (ADIS). On that note, several protocols of exercising have been studied such as asymmetric spinal stabilization exercises (ASSE), scoliosis specific exercises, SEAS (scientific exercise approach to scoliosis), Pilates method, Schroth technique as well as a multidisciplinary program that except of the physical training includes a psychological therapy. In a recent study, patients who followed a personalized program that depended on the curve's type and aimed in strengthening the muscles on the concaved zone of the scoliotic curve showed a significant improvement in Cobb angle mainly in prone position [17]. In another

study, ADIS patients were assessed after a mean of two years of performing SEAS. The results showed a progress of scoliosis in less than 68% of the patients. In addition, there was an improvement in angular value ($p < 0.05$) unrelated to the curvature's magnitude and location and unrelated to the age, gender and duration of treatment [18]. Furthermore, Schroth technique seems quite helpful when the curve's angle is 10-30° and the exercise protocol is performed for at least 6 months in a row [19]. Moreover, a rehabilitation program for ADIS patients consisting of specialized exercises and cognitive behavioral therapy (CBT) seemed to be superior from a general physiotherapy program [20]. In another recent study, ADIS patients that followed the same program for 20 weeks seemed to have a significant improvement in domains like pain, disability, kinesiophobia, catastrophizing and quality of life. However, regarding the clinical deformity, there was improvement but not clinically significant. The benefits of this approach were present for one year at the minimum [21]. Similar benefits have been reported in women with thoraco-lumbar scoliosis that followed a therapeutic intervention based on Pilates Method. In these women, scoliosis angular values decreased by 38%, stretchiness improved by 80% and pain was critically decreased by 60% [22].

Operative approach


Surgery is usually considered when all conservative measures have failed. When the patient is not satisfied with their current condition and their symptoms insist and cause deterioration of their quality of life, surgical options have to be discussed considering all the benefits, the disadvantages and the possible complications. The type of surgical technique used depends on patient's age and clinical condition and on surgeon's preference.

The main goals of surgical treatment are pain reduction and improvement of deformity principally on the sagittal plane. Spinal fusion, using pedicle screws with or without the use of cages and grafts, through a posterior or/and an anterior approach is the most commonly used surgical technique. Surgical treatment appears to have better results than conservative treatment. According to a recent study including 49 patients operated for degenerative scoliosis, on the eight years fol-

low up 23% of patients had excellent results, 29% had good, 34% had good enough and 14% had inadequate results. In addition, pain was improved in the visual analog scale (VAS) from 7 to 2 and Cobb angle was improved approximately by 12° [1]. Similar results have been reported in another study including patients over 75 years old who underwent spinal reconstructive surgery. On the two years follow up, all patients had a significant improvement in radiographic evaluation and in Health-related quality of life (HRQOL), as well as in pain and disability. In contrast, conservatively treated patients did not show any improvement ($p>0.05$) [12]. Moreover, in another recent study, patients with symptomatic lumbar scoliosis who underwent spinal fusion, had better results than patients who followed a conservative protocol with physical therapy, facet injections, oral administration of different medications (non-steroidal anti-inflammatory drugs, opioids, gabapentin) and nerve root injections for back and leg pain management. At the two years follow up, Oswestry Disability Index (ODI) and Scoliosis Research Society-22 Score (SRS-22) were more improved ($p<0.001$) in the operative group [23]. Even though patients that chose to proceed with surgery were in worse clinical condition than those who preferred the conservative approach, at the two years follow up they showed a significant improvement in domains like pain, disability and quality of life [24, 25].

Pharmacological Approach

Adults with scoliosis often suffer from persistent back or leg pain that can lead to disability. Constant pain is usually managed with a combination of oral medications as non-steroidal anti-inflammatory drugs, antidepressants and opiates administered for only a short period of time [26]. Indeed, narcotic analgesics, muscle relaxants and tricyclic antidepressants can be useful in pain management, especially of night pain. Gabapentin seems to be beneficial in managing neurogenic pain and it seems to be well tolerated by elderly population [27]. However, all these drugs come along with side effects such as gastrointestinal dysfunction and acid-peptic disease and must be used with caution. Moreover, focused epidural, facet injections or nerve root blocks can be used both for diagnostic and pain-relieving reasons because they can help patients localize the source of their pain [5, 9].

In conclusion, a variety of therapeutic approaches for adult scoliosis exist. The type of treatment depends on various factors and has to be patient specific. The prevailing aspect is that patients with moderate scoliosis should seek conservative treatment first, as long as there isn't any serious deterioration in their symptoms or quality of life. Conservative management should be exhausted before any decision for surgery is taken. The surgeon has to assess the benefits and risks of such decision taking into consideration patient's best interests. 

Conflict of interest

The authors declare no conflict of interest.

REFERENCES

1. Palmisani M, Dema E, Cervellati S. Surgical treatment of adult degenerative scoliosis. *Eur Spine J* 2013; 22:S829-33.
2. Ersberg A, Gerdhem P. Pre- and postoperative quality of life in patients treated for scoliosis. *Acta Orthop* 2013; 84(6):537.
3. Weiss HR, Turnbull D. Non-specific chronic low back pain in patients with scoliosis-an overview of the literature on patients undergoing brace treatment. *J Phys Ther Sci.* 2019; 31(11):960.
4. Silva FE, Lenke LG. Adult degenerative scoliosis: evaluation and management. *Neurosurg Focus* 2010; 28(3).
5. Bettany-Saltikov J, Turnbull D, Ng SY, et al. Management of Spinal Deformities and Evidence of Treatment Effectiveness. *Open Orthop J* 2017; 2911:1521-1547.
6. Palazzo C, Montigny JP, Barbot F, et al. Effects of Bracing in Adult with Scoliosis: A Retrospective Study. *Arch Phys Med Rehabil* 2017; 98(1):187-190.
7. McAviney J, Mee J, Fazalbhoy A, et al. A systematic literature review of spinal brace/orthosis treatment for adults with scoliosis between 1967 and 2018: clinical outcomes and harms data. *BMC Musculoskelet Disord* 2020 8;21(1):87.
8. Teles AR, Mattei TA, Righesso O, Falavigna A. Ef-

- fectiveness of Operative and Nonoperative Care for Adult Spinal Deformity: Systematic Review of the Literature. *Global Spine J* 2017; 7(2):170-178.
9. Afolayan JO, Shafafy R, Maher M, et al. Assessment and management of adult spinal deformities. *Br J Hosp Med (Lond)* 2018; 2;79(2):79-85.
 10. Smith JS, Shaffrey CI, Glassman SD, et al; Spinal Deformity Study Group. Risk-benefit assessment of surgery for adult scoliosis: an analysis based on patient age. *Spine (Phila Pa 1976)*. 2011; 1:36(10):817-24.
 11. Özyemişçi Taşkıran Ö. Rehabilitation in adult spinal deformity. *Turk J Phys Med Rehabil*. 2020; 16;66(3):231-243.
 12. Sciubba DM, Scheer JK, Yurter A, et al; International Spine Study Group (ISSG). Patients with spinal deformity over the age of 75: a retrospective analysis of operative versus non-operative management. *Eur Spine J* 2016; 25(8):2433-41.
 13. Zaina F, Poggio M, Donzelli S, et al. Can bracing help adults with chronic back pain and scoliosis? Short-term results from a pilot study. *Prosthet Orthot Int* 2018; 42(4):410-414.
 14. Protopsaltis TS, Boniello AJ, Schwab FJ. Management of Spinal Deformity in Adult Patients with Neuromuscular Disease. *J Am Acad Orthop Surg* 2016; 24(9):634-44.
 15. Brooks JT, Sponseller PD. What's New in the Management of Neuromuscular Scoliosis. *J Pediatr Orthop* 2016; 36(6):627-33.
 16. Graham RB, Sugrue PA, Koski TR. Adult Degenerative Scoliosis. *Clin Spine Surg* 2016; 29(3):95-107.
 17. Ko JY, Suh JH, Kim H, et al. Proposal of a new exercise protocol for idiopathic scoliosis: A preliminary study. *Medicine (Baltimore)* 2018; 97(49):e13336.
 18. Negrini A, Negrini MG, Donzelli S, et al. Scoliosis-Specific exercises can reduce the progression of severe curves in adult idiopathic scoliosis: a long-term cohort study. *Scoliosis* 2015; 11; 10:20.
 19. Park JH, Jeon HS, Park HW. Effects of the Schroth exercise on idiopathic scoliosis: a meta-analysis. *Eur J Phys Rehabil Med* 2018; 54(3):440-449.
 20. Alanazi MH, Parent EC, Dennett E. Effect of stabilization exercise on back pain, disability and quality of life in adults with scoliosis: a systematic review. *Eur J Phys Rehabil Med* 2018; 54(5):647-653.
 21. Monticone M, Ambrosini E, Cazzaniga D, et al. Adults with idiopathic scoliosis improve disability after motor and cognitive rehabilitation: results of a randomised controlled trial. *Eur Spine J* 2016; 25(10):3120-3129.
 22. Alves de Araújo ME, Bezerra da Silva E, Bragade Mello D, et al. The effectiveness of the Pilates method: reducing the degree of non-structural scoliosis, and improving flexibility and pain in female college students. *J Bodyw Mov Ther* 2012; 16(2):191-8.
 23. Kelly MP, Lurie JD, Yanik EL, et al. Operative Versus Nonoperative Treatment for Adult Symptomatic Lumbar Scoliosis. *J Bone Joint Surg Am* 2019; 20;101(4):338-352.
 24. Smith JS, Lafage V, Shaffrey CI, et al. Outcomes of Operative and Nonoperative Treatment for Adult Spinal Deformity: A Prospective, Multicenter, Propensity-Matched Cohort Assessment with Minimum 2-Year Follow-up. *Neurosurgery* 2016; 78(6):851-61.
 25. Smith JS, Shaffrey CI, Berven S, et al; Spinal Deformity Study Group. Improvement of back pain with operative and nonoperative treatment in adults with scoliosis. *Neurosurgery* 2009; 65(1):86-93;93-4.
 26. Diebo BG, Shah NV, Boachie-Adjei O, Zhu F, Rothenfluh DA, Paulino CB, Schwab FJ, Lafage V. Adult spinal deformity. *Lancet*. 2019; 13;394(10193):160-172.
 27. Kotwal S, Pumberger M, Hughes A, Girardi F. Degenerative scoliosis: a review. *HSS J*. 2011; 7(3):257-64.

READY - MADE
CITATION

Kontopanou M, Benetos IS, Pneumaticos SG, Vlamis I. Adult Scoliosis: Therapeutic Approach and Spinal Pain Management. *Acta Orthop Trauma Hell* 2022; 73(3): 306-311.