

Conservative versus surgical treatment of spondylodiscitis

Aristeides Koutsopoulos¹, Ioannis S. Benetos¹, Ioannis Vlamis¹, Spyridon G. Pneumaticos¹

^{13rd} Department of Orthopaedic Surgery, University of Athens, KAT Hospital, Athens, Greece

ABSTRACT

Early diagnosis and aggressive initial treatment are essential for a satisfactory outcome of patients with spondylodiscitis. However, management strategies are still controversial. Aiming to compare the results of conservative and surgical treatment of patients with spondylodiscitis, a review of the current literature was conducted by using the online Pubmed database and the following keywords: (“treatment” OR “management” OR “therapy”) AND (“vertebral osteomyelitis” OR “spondylodiscitis” OR “spinal infection” OR “discitis”). The search included only comparative prospective or retrospective studies, comparing conservative versus surgical management, in terms of outcome and complications. Initially, 407 studies were identified after a primary search on the online Pubmed database. Finally, 14 studies were included in the review (12 retrospective and 2 prospective studies). In conclusion, the initial treatment of spondylodiscitis should be conservative with bed rest, bracing and proper antibiotic treatment lasting for at least 8 weeks. However, in cases of neurological deficit, abscess formation, deformities and failure of conservative management, surgical treatment is required. Although conservative treatment is associated with a higher rate of chronic back pain and long-term deformities, it is also associated with a lower mortality rate in comparison to surgical management. Perioperative complications still remain an issue in surgically treated patients; however, patients’ satisfaction and quality of life are higher compared to those of conservatively treated patients, indicating that treatment of spondylodiscitis should be individualized taking into consideration patients’ clinical presentation, imaging studies and the virulence of the responsible pathogen.

Key Words: spondylodiscitis ; vertebral osteomyelitis; spinal infection; treatment; management

Introduction

Spondylodiscitis accounts for 2-7% of all osteomyelitis cases. It affects mainly elderly immunocompromised patients; however, it can also affect young patients in association with HIV infection, immunodeficiency syndrome and intravenous drug use. The most common pathogenic mechanism is hematogenous spread of microorganisms which may occur in any condition that causes bacteremia, such as urogenital, respiratory or soft tissue infection. The most common responsible microorganisms are *Staphylococcus aureus* (30-55%), *E. coli*, *Salmonella*, *Enterococcus*, *Proteus mirabilis*, *Pseudomonas aeruginosa* (65% of intravenous drug users), *Streptococcus viridans* and *Staphylococcus epidermidis* [1].

Typically, the initial symptom is slowly increasing,

continuous and localized back or neck pain, which is exacerbated during rest, especially at night. Additional symptoms may include muscle spasms, weight loss, lower back, groin or buttock pain, and in advanced stages of disease symptoms of radiculopathy and myelopathy. Serum inflammation markers such as C-reactive protein (CRP) and erythrocyte sedimentation rate (ESR) are usually increased. While plain X-rays become positive only in the advanced stages of the disease, Magnetic Resonance Imaging (MRI) becomes positive very early in its course and has been established as the imaging method of choice. Lesion biopsy and isolation of the responsible pathogen is highly important and should be attempted in any case. Computed Tomography (CT)-guided biopsy is the method of

choice because it allows a sample to be taken from the core of the lesion with safety and accuracy [2-4].

Early diagnosis and aggressive conservative or surgical treatment are essential for a satisfactory outcome. The primary goals of management of spondylodiscitis are the isolation of the responsible microorganism, the prevention of bacteremia and sepsis, the elimination of the infection, the long-term pain relief, the prevention or reversal of the neurological deficit, the restoration of spinal stability, the correction of spinal deformity and the prevention of the recurrence of the disease. Initial treatment of bacterial and parasitic infections is usually conservative with bed rest and intravenous administration of antibiotics for at least 4-6 weeks, depending on the extent of the infection and the responsible microorganism. Antibiotic treatment should not be ceased before serum inflammatory markers return to normal. Although bed rest is indicated in the very early stages of treatment, early mobilization of the patient with the help of a brace is recommended. Basic treatment principles also include improving the patient's diet and immune status as well as treating ectopic infections, for example urinary or respiratory tract infections [2, 5-6].

Indications for a shift from conservative to surgical treatment are the persistence or worsening of the infection despite adequate antibiotic treatment and the presence of pharmacological side effects, as renal or hepatic impairment, limiting further use of the appropriate antibiotics in the required dosages. Surgical treatment is also indicated in cases of progressive spinal deformity and instability, formation of spinal abscess or appearance of neurological signs due to nerve compression. Indeed, spinal cord compression requires urgent surgical intervention. However, it may prove useless if the paralysis has been established for more than 24-36 hours [7].

The key to successful surgical treatment is radical surgical debridement. This has been widely proven in the treatment of tuberculous spondylitis, but it also applies in cases of pyogenic spinal discitis. Anterior approach of the spine and radical surgical debridement and reconstruction of the anterior spinal column using bone graft are indicated in patients with intravertebral abscesses without major bone destruction, deformity and instability. Anterior spinal approach is also effective in

decompressing the spinal canal if the anterior spinal elements are involved. Posterior spinal fusion after anterior spinal surgery is indicated in cases with significant kyphotic deformity or after radical surgical debridement and corpectomy at multiple levels. Hardware and grafts for spinal fusion can be used at the site of the infection, provided that radical surgical debridement is fully achieved [1, 6-8].

The aim of the current study was to review and compare the results of conservative and surgical treatment of patients with spondylodiscitis. For this reason, a review of the current literature was conducted using the online Pubmed database and following the PRISMA Guidelines. Article titles were searched by using the following keywords: ("treatment" OR "management" OR "therapy") AND ("vertebral osteomyelitis" OR "spondylodiscitis" OR "spinal infection" OR "discitis"). Inclusion criteria in the review were: comparative prospective or retrospective studies, comparing conservative versus surgical management, in terms of outcome and complications. Studies published in non-English language, non-comparative studies, reviews, case reports and study protocols were excluded from the review. Studies in children and adolescents were also excluded. Initially, 407 studies were identified after a primary search on the online Pubmed database. After screening of titles and abstracts, 302 articles were excluded as inappropriate. From the remaining 105 studies, 91 were rejected for various reasons (figure 1), leaving 14 studies for analysis (12 retrospective and 2 prospective studies).

Discussion

Pyogenic Spondylodiscitis

A retrospective study by Karadimas *et al*, compared the results of conservative and surgical treatment in 163 patients hospitalized for spondylodiscitis. Seventy patients received conservative treatment, 56 patients underwent posterior decompression and 37 patients underwent posterior decompression and stabilization. At one-year follow-up, 11% of patients treated conservatively had to be operated, while no one had developed neurological symptoms. Among patients receiving decompression without stabilization, the reoperation rate was 42%, while 26% had developed neurological symptoms. Among patients receiving combined stabilization and decompression, the reop-

eration rate was 16%, while 30% had developed neurological symptoms. The authors concluded that conservative treatment was effective in 89% of patients with spondylodiscitis, especially in those with mild clinical symptoms and no neurological signs [9].

Similarly, another retrospective comparative study by Valancius *et al*, including 208 patients, described the results of conservative versus surgical treatment of patients with infectious spondylodiscitis. Conservative treatment with antibiotics and bracing was applied in 91 patients, while 94 patients underwent posterior debridement with or without pedicle screw instrumentation and 23 patients underwent anterior debridement with or without pedicle screw instrumentation. The study results showed that the rate of successful conservative treatment was 87%. The authors concluded that administration of antibiotics and bracing is a safe and effective treatment of patients with spondylodiscitis without any complications [10].

In another retrospective observational cohort study including 27 patients with single-level uncomplicated lower thoracic or lumbar pyogenic spondylodiscitis, Nasto *et al*, compared the application of a standard thoracolumbosacral orthosis rigid bracing for 3–4 months ($n = 12$) with posterior percutaneous pedicle screw spinal instrumentation followed by a soft brace for 4 weeks ($n = 15$). All patients received resistance-adopted antibiotics. In 6 months follow-up, patients subjected to surgical treatment reported lower pain scores and improved quality of life. However, no statistically significant differences were found in 9 months follow-up. The authors concluded that surgical treatment did not offer any advantage in healing time over thoracolumbosacral orthosis rigid bracing because infection clearance mainly depends on proper antibiotic administration [11].

Wirtz *et al*, in a retrospective study, assessed the therapeutic outcomes of 59 patients with lumbar or thoracic spondylodiscitis. Thirty five patients were treated conservatively with bed rest, bracing and proper antibiotics, while 24 patients underwent surgery, due to abscess formation or progressive neurological deterioration. Mean time of immobilization was 5.9 weeks for patients undergoing surgical procedures and 7.8 weeks for patients treated conservatively. The authors concluded that conservative and surgical treatment are

not rivals but rather complementary to one another, as they are both indicated for management of spondylodiscitis [12].

A recent, single center, retrospective cohort study by Alas *et al*, enrolled 116 patients with spondylodiscitis. Seventy three patients received only conservative treatment (antimicrobial treatment and analgesics) and 43 patients received surgical plus conservative treatment. Patients treated surgically were significantly younger and less frail. Surgical treatment was significantly associated with decreased 30-day and 1-year mortality rate in comparison to conservative treatment, while an increased frailty index was associated with higher short-term mortality, regardless of intervention [13].

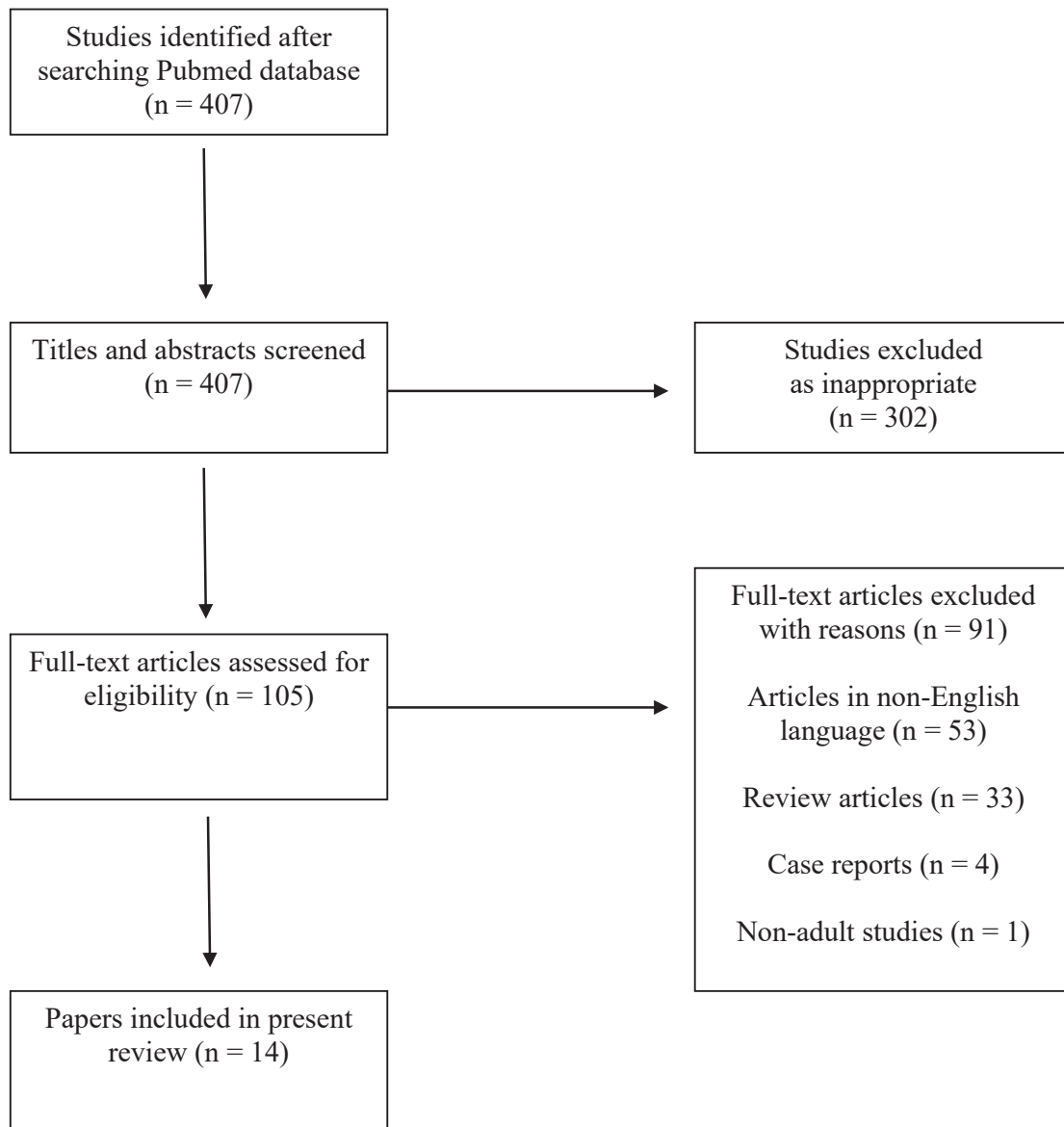
A small prospective study by Waheed *et al*, enrolled 44 patients with spontaneous spondylodiscitis. Twelve patients received conservative treatment with bed rest, bracing and proper antibiotics, 10 patients underwent laminectomy, debridement and open biopsy, and 22 patients underwent laminectomy and fusion. The authors concluded that once diagnosis is confirmed, early and prolonged administration of proper antibiotics is recommended for the treatment of spontaneous spondylodiscitis [14].

Quality of life after surgical and conservative treatment of spondylodiscitis was evaluated in a recent, retrospective, single-center study by Behmanesh *et al*. From 210 patients with spondylodiscitis, 155 underwent a surgical procedure and 55 were treated conservatively. Patients treated surgically reported a significantly improved quality of life in comparison to conservatively managed patients [15]. A similar study by Woertgen *et al*, retrospectively investigated 62 patients with pyogenic spinal infection. Among them, 28 patients underwent conservative management and 34 patients were operated. Patients treated with a surgical procedure reported a slightly better quality of life and self-reported satisfaction levels [16].

Hematogenous pyogenic vertebral osteomyelitis

Another recent retrospective study by Canoui *et al*, evaluated conservative and surgical treatment in 90 patients with hematogenous pyogenic vertebral osteomyelitis. 69% of the patients ($n = 62$) were treated conservatively, while 31% ($n = 28$) received a combination of conservative and operative treatment. At

Figure 1. Study flowchart



4-months follow up, although there was no difference in neurological improvement between the two groups, patients treated both surgically and conservatively experienced less pain. However, at one-year follow up, there was no difference in infection-related complications between the two groups [17].

In another retrospective study, Hadjipavlou *et al*,

compared the conservative and operative management among 101 patients with hematogenous pyogenic vertebral osteomyelitis. All patients received antibiotics, initially intravenously and then orally. Sixty-six patients received an operation, while the rest were treated conservatively. Among patients treated conservatively, 64.3% continued to report chronic back

pain. In the surgically treated group, only 26.3% of the patients reported chronic back pain at disabling levels. The authors concluded that the outcome of treatment depends on the type of infection and the severity of neurologic involvement prior to the treatment. Conservative treatment may control the infection; however, surgery may prevent deformities and chronic back pain [18].

The therapeutic outcomes of hematogenous vertebral osteomyelitis caused by methicillin-resistant *Staphylococcus aureus* were evaluated in a prospective cohort study by Park *et al.* All of the 139 patients received intravenous antibiotics as an initial treatment, for a mean duration of 50 days. Surgical debridement was performed in 40 patients and CT-guided aspiration drainage was performed in 38 patients. At multivariate analysis, surgical debridement was associated with prolonged hospitalization, while longer duration of antibiotic therapy was associated with lower relapse rates [19].

A retrospective multicentre study by Colmenero *et al.* included 219 adult patients with vertebral osteomyelitis. 48% (n = 105) of patients suffered from brucellar vertebral osteomyelitis, 33% (n = 72) suffered from pyogenic vertebral osteomyelitis and 19% (n = 42) suffered from tuberculous vertebral osteomyelitis. Among them, 119 patients received only conservative treatment and 100 patients received both conservative and surgical treatment. The outcome of the operated patients did not differ significantly from that of patients treated only conservatively, although the mean duration of hospitalization was significantly higher in the group of operated patients [20].


HIV-infected patients

In 2009, Sobottke *et al.* conducted a multicenter retrospective study comparing the outcome of surgical versus conservative treatment in HIV(+) patients with spondylodiscitis. The study included 20 patients; 10 were treated conservatively with antimicrobial agents and 10 received an operation. The authors concluded that surgical management of spondylodiscitis in

HIV(+) patients is not associated with an increased surgical complication rate. As increased perioperative morbidity is not expected, HIV infection should not affect decision-making regarding conservative or surgical management of spondylodiscitis [21].

Elderly patients

A retrospective case series by Sobottke *et al.*, compared conservative and operative treatment of spondylodiscitis in patients over 65 years of age. Sixteen patients were managed conservatively and 16 patients were managed surgically. Neurologic deficit, sepsis, instability, abscess formation and impending deformities were indications for surgery, while conservative treatment was applied in patients with mild symptoms. The authors found that the complication rate of surgical treatment of elderly patients with spondylodiscitis was not higher than that observed in younger patients. No difference was also found regarding pain and quality of life; however, satisfaction was higher in elderly patients receiving operation. The authors concluded that age should not influence the decision making regarding conservative or surgical treatment of patients with spondylodiscitis [22].

In conclusion, initial conservative treatment of uncomplicated spondylodiscitis with bed rest, bracing and proper antibiotics for at least 8 weeks, remains the gold standard. However, in cases of neurological deficit, abscess formation, deformities, and failure of conservative treatment, surgical treatment is required. Conservative treatment is associated with a higher rate of chronic back pain and long-term spinal deformities; however, it is also associated with a lower mortality rate in comparison to surgical treatment. Perioperative complications still remain an issue in surgically treated patients; however, patients' satisfaction and quality of life seems to be higher than those of conservatively treated patients, indicating that treatment of spondylodiscitis should be individualized taking into consideration patients' clinical presentation and imaging studies and the virulence of the responsible pathogen. 

REFERENCES

1. Skaf GS, Domloj NT, Fehlings MG, Bouclaous CH, Sabbagh AS, Kanafani ZA, et al. Pyogenic spondylodiscitis: an overview. *J Infect Public Health*. 2010;3(1):5-16.
2. Asamoto S, Doi H, Kobayashi N, Endoh T, Sakagawa H, Iwanaga Y, et al. Spondylodiscitis: diagnosis and treatment. *Surg Neurol*. 2005 Aug;64(2):103-108; discussion 108.
3. Cottle L, Riordan T. Infectious spondylodiscitis. *J Infect*. 2008 Jun;56(6):401-412.
4. Gentile L, Benazzo F, De Rosa F, Boriani S, Dallagiacomma G, Franceschetti G, et al. A systematic review: characteristics, complications and treatment of spondylodiscitis. *Eur Rev Med Pharmacol Sci*. 2019 Apr;23(2 Suppl):117-128.
5. Gouliouris T, Aliyu SH, Brown NM. Spondylodiscitis: update on diagnosis and management. *J Antimicrob Chemother*. 2010 Nov;65 Suppl 3:iii11-24.
6. Zarghooni K, Röllinghoff M, Sobottke R, Eysel P. Treatment of spondylodiscitis. *Int Orthop*. 2012 Feb;36(2):405-411.
7. Guerado E, Cerván AM. Surgical treatment of spondylodiscitis. An update. *Int Orthop*. 2012 Feb;36(2):413-420.
8. Nickerson EK, Sinha R. Vertebral osteomyelitis in adults: an update. *Br Med Bull*. 2016 Mar;117(1):121-138.
9. Karadimas EJ, Bunger C, Lindblad BE, Hansen ES, Hoy K, Helmig P, et al. Spondylodiscitis. A retrospective study of 163 patients. *Acta Orthop*. 2008 Oct;79(5):650-659.
10. Valancius K, Hansen ES, Høy K, Helmig P, Niedermann B, Bünger C. Failure modes in conservative and surgical management of infectious spondylodiscitis. *Eur Spine J*. 2013 Aug;22(8):1837-1844.
11. Nasto LA, Colangelo D, Mazzotta V, Di Meco E, Neri V, Nasto RA, et al. Is posterior percutaneous screw-rod instrumentation a safe and effective alternative approach to TLSO rigid bracing for single-level pyogenic spondylodiscitis? Results of a retrospective cohort analysis. *Spine J*. 2014 Jul 1;14(7):1139-1146.
12. Wirtz DC, Genius I, Wildberger JE, Adam G, Zilkens KW, Niethard FU. Diagnostic and therapeutic management of lumbar and thoracic spondylodiscitis--an evaluation of 59 cases. *Arch Orthop Trauma Surg*. 2000;120(5-6):245-251.
13. Alas H, Fernando H, Baker JF, Brown AE, Bortz C, Naessig S, et al. Comparative outcomes of operative relative to medical management of spondylodiscitis accounting for frailty status at presentation. *J Clin Neurosci*. 2020 May;75:134-138.
14. Waheed G, Soliman MAR, Ali AM, Aly MH. Spontaneous spondylodiscitis: review, incidence, management, and clinical outcome in 44 patients. *Neurosurg Focus*. 2019 Jan 1;46(1):E10.
15. Behmanesh B, Gessler F, Duetzmann S, Seifert V, Weise L, Setzer M. Quality of Life Following Surgical and Conservative Therapy of Pyogenic Spinal Infection: A Study of Long-term Outcome in 210 Patients. *J Neurol Surg A Cent Eur Neurosurg*. 2021 Mar 9.
16. Woertgen C, Rothoerl RD, Englert C, Neumann C. Pyogenic spinal infections and outcome according to the 36-item short form health survey. *J Neurosurg Spine*. 2006 Jun;4(6):441-446.
17. Canoui E, Zarrouk V, Canoui-Poitrine F, Desmoulin U, Leflon V, Allaham W, et al. Surgery is safe and effective when indicated in the acute phase of hematogenous pyogenic vertebral osteomyelitis. *Infect Dis (Lond)*. 2019 Apr;51(4):268-276.
18. Hadjipavlou AG, Mader JT, Necessary JT, Muffoletto AJ. Hematogenous pyogenic spinal infections and their surgical management. *Spine (Phila Pa 1976)*. 2000 Jul 1;25(13):1668-1679.
19. Park KH, Chong YP, Kim SH, Lee SO, Choi SH, Lee MS, et al. Clinical characteristics and therapeutic outcomes of hematogenous vertebral osteomyelitis caused by methicillin-resistant *Staphylococcus aureus*. *J Infect*. 2013 Dec;67(6):556-564.
20. Colmenero JD, Jiménez-Mejías ME, Sánchez-Lora FJ, Reguera JM, Palomino-Nicás J, Martos F, et al. Pyogenic, tuberculous, and brucellar vertebral osteomyelitis: a descriptive and comparative study of 219 cases. *Ann Rheum Dis*. 1997 Dec;56(12):709-715.

21. Sobottke R, Zarghooni K, Krengel M, Delank S, Seifert H, Fätkenheuer G, et al. Treatment of spondylodiscitis in human immunodeficiency virus-infected patients: a comparison of conservative and operative therapy. *Spine (Phila Pa 1976)*. 2009 Jun 1;34(13):E452-458.
22. Sobottke R, Röllinghoff M, Zarghooni K, Schlüter-Brust K, Delank KS, Seifert H, et al. Spondylodiscitis in the elderly patient: clinical mid-term results and quality of life. *Arch Orthop Trauma Surg*. 2010 Sep;130(9):1083-1091.

READY - MADE
CITATION

Koutsopoulos A, Benetos IS, Vlamis I, Pneumaticos SG. Conservative versus surgical treatment of spondylodiscitis. *Acta Orthop Trauma Hell* 2022; 73(1): 75-81.