

Necrotising fasciitis of the lower extremity following streptococcal pharyngitis

Ch Ioannidis^{1,2}, B Cohen¹, S Giannacopoulou², P Alevras²

¹University College London Hospitals NHS Trust, London, UK

²IASO General Hospital, Athens, Greece

ABSTRACT

Necrotising fasciitis is a grave infectious process affecting the fascia, the overlying soft tissues, and, occasionally, the underlying muscle. Various bacteria can be the cause of this aggressive and fast progressing disease. Skin lacerations or surgical wounds are the portal of entry in most patients; however, hematogenous spread of the microorganism can occasionally initiate the process. Streptococcal pharyngitis (group A β hemolytic streptococcus - GAS) followed by necrotizing fasciitis of the lower limb is a very rare finding with only a few case reports found in the literature. Two such cases of necrotising fasciitis of the left lower limb with similar features treated by the same surgeon at two different hospitals in two different countries are presented. The outcome was favorable in both patients. The diagnostics and appropriate mode of treatment are reviewed. The importance of early surgical intervention is stressed, as it can save lives.

KEY WORDS: Necrotising fasciitis, myositis, lower limb, surgery, urgency, pharyngitis, streptococcus, gangrene.

Introduction

In the 16th century, Ambroise Paré described a gangrene-like condition that resembled today's "flesh-eating disease" (1). A similar soft-tissue infection was described during the American Civil War (2). In 1952, Wilson proposed the term "necrotising fasciitis" to replace terms like gangrenous erysipelas, hospital gangrene, acute cutaneous cellulitis, streptococcal gangrene, Meleney cellulitis, and others (3).

Necrotising fasciitis (NF) is a subset of the aggressive skin and soft tissue infections which cause ne-

crisis of the muscle fascia and subcutaneous tissue. Even today, the disease has a high mortality rate (1, 2). This infection typically travels along the poorly vascularized fascial plane leaving the overlying tissues initially unaffected, potentially delaying diagnosis and surgical intervention (4). The infectious process can rapidly spread to peri-fascial planes, causing a secondary infection of the overlying skin and underlying soft tissue and muscle (necrotising fasciomyositis). The estimated annual incidence in the United States in 2018 was 10.3 (National Inpatient Sample) and 8.7 (Watson Health Dataset) per

CORRESPONDING
AUTHOR,
GUARANTOR

Ch. Ioannidis MD DMD PhD, Consultant P/R Surgeon UCL Hospitals NHS Trust, UK, Assoc. Professor of Surgery, University of Leuven, Belgium, Ioannou Gennadiou Str. 18, Athens 11521, Greece, E-mail: ioannidc@otenet.gr

100,000 persons, respectively (5). The incidence has been demonstrated to be increasing, as in 2009 it was reported 4.3 infections per 100,000 (6). NF places significant demand upon hospital and medical resources. An Australian study reported that the mean hospital length of stay for survivors of NF was 36 days, and the average cost per patient during their stay was AUS \$ 64,517 (7).

NF can affect any part of the body; the extremities, however, the perineum and the truncal areas are the most commonly involved. Most patients present with signs of inflammation such as erythema, swelling and pain at the affected site (6, 8, 9, 10). However, these symptoms may be non-specific at first, which often causes the diagnosis to be missed. Severe pain disproportionate to local findings, and occasionally associated with systematic toxicity, should raise the suspicion of necrotising fasciitis (6, 11, 12). As the infection progresses, the skin becomes increasingly erythematous and tense with indistinct margins. It may change color from red-purple to a dusky blue before progression to necrosis and formation of bullae (blistering) which eventually become hemorrhagic. Blistering is due to ischemia-induced necrolysis, as the invading organisms cause progressive thrombosis of vessels that penetrate the fascia to supply skin (13). Crepitus may be palpated over the affected area due to gas produced by aerobic and anaerobic bacteria. The skin lesions may turn black and form a necrotic crust, with fascial tissue and brown-grayish secretions underneath the crust (6). Symptoms may develop over a period of hours to several days, and presentations vary (11). Patients presenting at an advanced stage may show signs of systemic shock and sepsis. They pose extra diagnostic difficulties since they may be confused, agitated or have a reduced level of consciousness.

The most common portals of entry are sites of prior surgery or trauma, contusions and skin lesions (1, 6, 12). Malignancies and other conditions can play a role as predisposing factors. NF, however, can also occur idiopathically, with no previous history of surgery, trauma, skin lesions etc. Pharyngitis and early hematogenous spread of the infection is a very rare occurrence. Our aim is to present two cases of otherwise healthy patients, who shortly after strep-

tococcal pharyngitis developed NF of the left lower extremity. The history, clinical course, treatment and follow-up of this disease are reviewed and the importance of early diagnosis and surgical intervention is discussed.

Case One

A 45-year-old previously healthy male patient (A. M.) was referred by his general practitioner (GP) to the Accident & Emergency Department (A&E) at the University College Hospital, London (UCLH NHS Trust) because of pain in his left hip and thigh. Four days earlier he had visited his GP because of a sore throat, for which amoxicillin (capsules 500mgr, 3xdaily) was prescribed. Two days later, the patient returned to his GP complaining of pain in the left hip/thigh area. He was a denizen of the gym; therefore, some kind of muscle or hip injury was suspected and ibuprofen (tablets 400mgr, 3-4xdaily) was prescribed with little effect. Thence, he was referred to the A&E Dept. of the UCH. At arrival, the patient was pyrexial (38.3 C), and complained of severe pain in and around his left hip and thigh. Orthopedic physical examination revealed erythema and tenderness of the skin over the left thigh. No other abnormal physical signs were detected. Plain x-rays of the left femur, left hip joint and pelvis were within normal limits. A CT-scan showed non-specific edema of the soft tissues of the left thigh (skin, subcutaneous fat and muscles). Laboratory values were: AP 100/70, pulse 90/min, PA 22/min, Hb 11.5 gr/dL, leucos 16,300/ml, CRP 18.3, Na⁺ 132 mmol/L, creatinine 1.6 mg/dL, glucose 106 mg/dL. A throat swab was taken which showed the presence of group A β -hemolytic streptococci. The consultant orthopedic surgeon (B.C) was highly suspicious of a necrotic infection and together with the consultant P/R surgeon on call (Ch. I) carried out a "finger-test" (small skin incision under local anesthesia over the area of maximal suspicion, blunt dissection down to the fascia and examination of the fascia with the finger. A finger along the fascial planes that easily dissects the overlying tissue without resistance was a positive test. Having established a differential diagnosis of necrotising fasciitis, the patient was taken to the operating theatre, where under general anesthe-

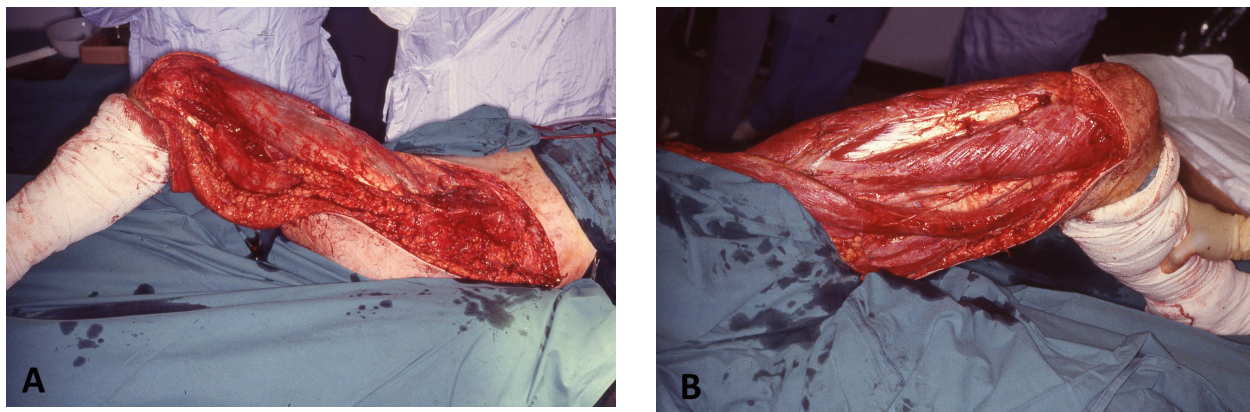


Fig.1. Patient one after surgical debridement of left thigh/trunk area. A. Lateral aspect. B. Medial aspect.

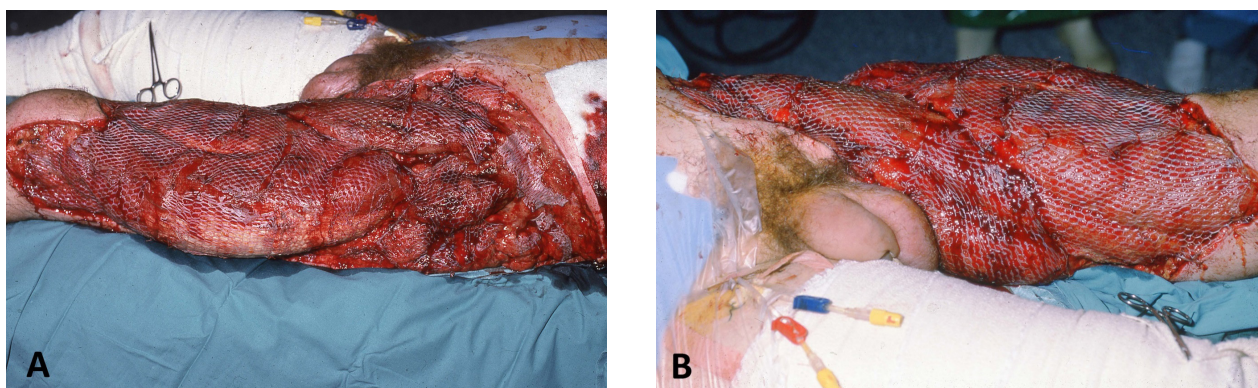


Fig.2. Patient one after cover of thigh/trunk defect with meshed skin grafts. A. Lateral aspect. B. Median aspect.

sia the suspicious skin, underlying fat and necrotic fascia of the left thigh and part of the left trunk were surgically debrided. The left rectus femoris muscle looked clinically necrotic (blackish, brittle) and was also debrided (Fig. 1). The patient was transferred to ICU and the triple antibiotic regimen (initiated in theatre) was continued. Postoperatively, the patient's condition improved dramatically. Further surgical exploration was conducted 24h later and further debridement of peripheral soft tissues and muscle parts was performed. Another two surgical debridements had to follow till all necrotic tissue was removed and the patient's condition stabilized. Seven days later he was returned to the ward. Blood cultures showed the presence of group A β -hemolytic streptococcus. After several days (d 14) and two consecutive negative wound swabs, the left extremity/trunk defect was covered with meshed split thickness skin grafts harvested from the right

thigh. There was a 100% take of the skin grafts (Fig. 2) and the patient was discharged from hospital in a good condition on day 23. He received intensive kinesio/physiotherapy and could return to normal physical activities three months after discharge. Follow-up at 8 months showed a normally functioning and aesthetically acceptable left lower limb (Fig. 3). The patient has been healthy and well, and free of symptoms for five years.

Case Two

A 46-year-old white male patient was admitted to the department of internal medicine at IASO General Hospital, Athens (S. G) with fever, weakness, general malaise and vertigo. Five days previously, while skiing in Switzerland, he felt unwell (sore throat, pyrexial, general malaise), and was prescribed antibiotics (amoxicillin tabs. 500mgr, 3xdaily) by the local general practitioner. Three days later

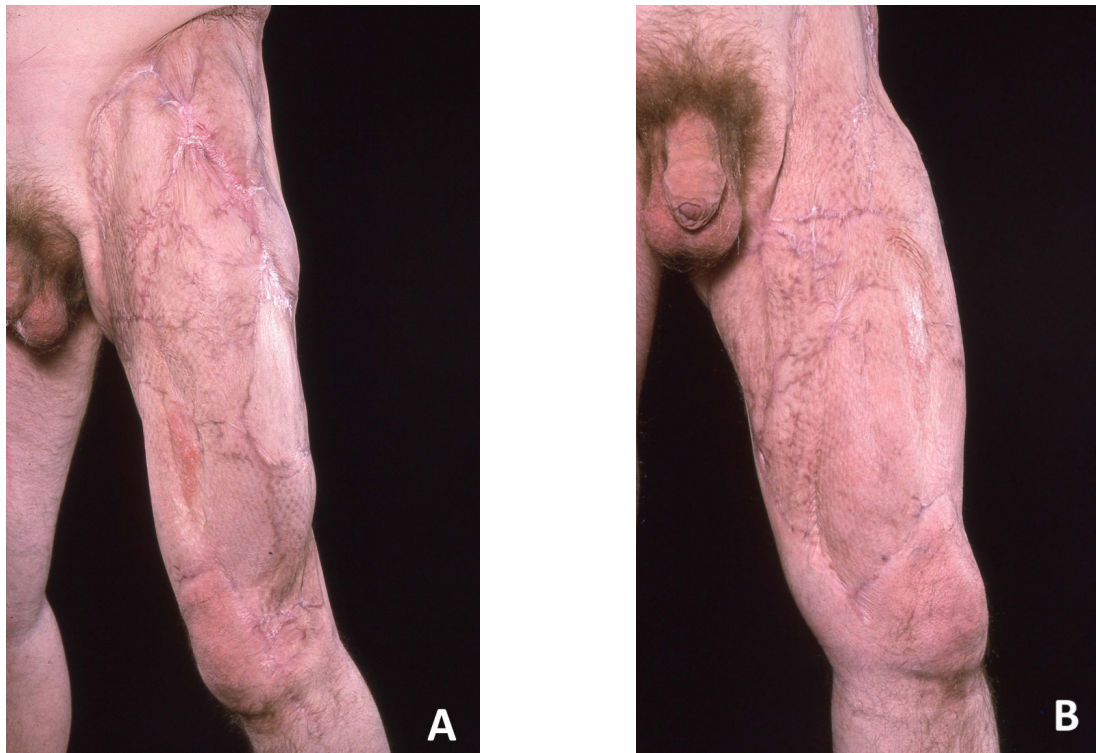


Fig.3. Patient one eight months postoperatively. A. Lateral aspect. B. Medial aspect.

his situation did not improve and he returned to his homeland (Athens, Greece). Upon telephonic consultation with his internist, hospital admission was suggested. From the medical history, tonsillectomy and hemorrhoidectomy were reported. On physical examination, the patient presented septic. His pharynx was erythematous and the skin of the left thigh showed signs of cellulitis (Fig. 4). Temperature was 37.9C, pulse 100/min, arterial pressure 70/50 mmHg, respiration 20/min, Hb 15.9 g/dL, Ht 45.3 %, leucocytes 17,330 (neutrophils 96%), SR 92, CRP 57.8 mg/dL, platelets 303,000, urea (BUN) 52 mg/dL, creatinine 1.3 mg/dL, Na⁺ 139mmol/L, K⁺ 4mmol/L, glucose 128mg/dL, D Dimers 2,688 ng/mL, CPK 527 IU/L (LRINEC score 5). A pharyngeal swab was taken for culture, which grew group A β -hemolytic streptococcus. The patient was resuscitated and put on IV antibiotics (clindamycin/Dalacin 600mg 3xdaily, moxifloxacin/Avelox 400mg once daily, amikacin/Briklin 1gr once daily). The following day his condition deteriorated; Hb 11.2 g/dL, Ht 32.8%, leucocytes 28,120 (neutrophils 94%), CRP 39.1 mg/dL, platelets 219,000, BUN 70

mg/dL, creatinine 2.2 mg/dL, Na⁺ 137mmol/L, K⁺ 4.1mmol/L, glucose 150 mg/dL, CPK 448 IU/L (LRINEC score 9). The antibiotic regimen was adapted (daptomycin/Cubicin 700mg once daily, clindamycin/Dalacin 600mg 3xdaily, doripenem/Doribax 500mg 3xdaily). An ultrasound of the left thigh showed oedema of the skin and adipose tissue, as well as increased vascularity of the anterior surface of the thigh, suggestive for cellulitis. The sartorius muscle and to a lesser extent the vastus medialis were edematous. There was no gas or fluid collection. The left inguinal lymph nodes were somewhat enlarged. The MRI of the left thigh showed extensive oedema of the skin and fat, a thickened deep fascia as well as thickening of the sartorius muscle, and to a lesser extent of the vastus medialis. There was a limited fluid collection around the sartorius muscle. At this point, surgical consultation (Ch. I) was sought and as the clinical picture was suggestive of necrotising fasciitis, a "finger-test" (and frozen sections) was suggested. It is worth noting that the infectious disease specialist wrote: "Even if the clinical and radiological picture is against a possi-

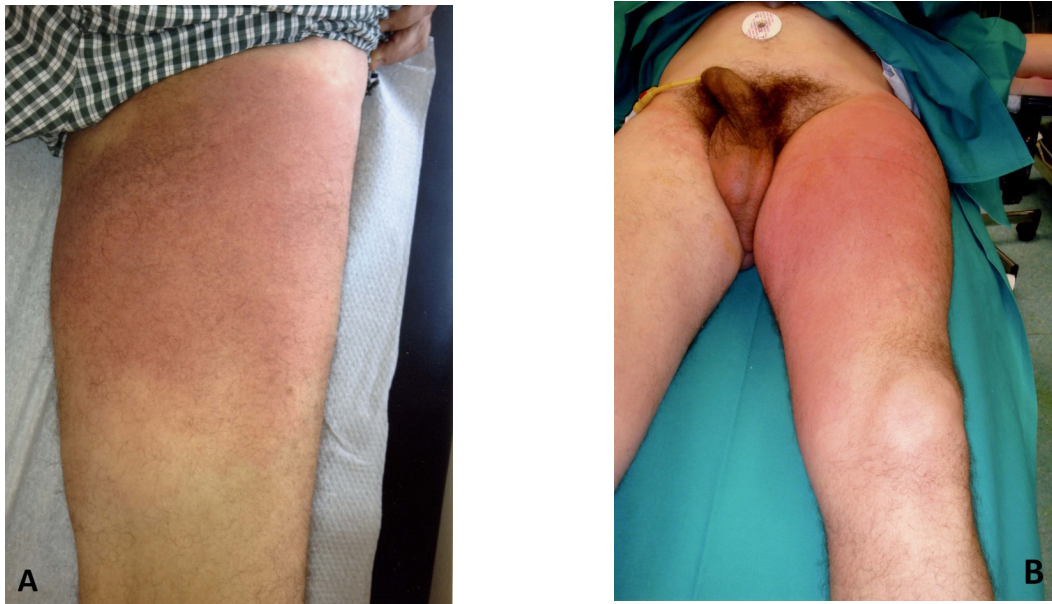


Fig.4. Left thigh of patient two. A. On day one. B. On day two. The erythema is markedly more extensive.

ble necrotising fasciitis, I agree with the minimally invasive test (finger-test by P/R surgeon) in order to exclude NF". The evening of day 2, under local anesthesia a small skin incision on the anterior surface of the patient's left thigh was performed with immediate pus flow through the wound (Fig. 5). The "finger-test" was positive. A small fat/fascia tissue specimen was resected and sent for frozen section. According to the pathology report, the adipose/connective tissue showed extensive necrotic inflammation, which extended to the fibrocollagenous septa, around the vessels and into the fatty tissue. There were sites of liponecrosis (Fig. 6). Furthermore, congested vessels and sites of recent hemorrhage could be identified (Fig. 6). The histologic picture along with the clinical picture was highly suggestive of necrotising fasciitis. The patient was taken to the operating theatre, where under general anesthesia a wide surgical debridement of the skin, adipose tissue and fascia of the left thigh was performed. Necrotic parts of the left sartorius muscle and the vastus medialis were also excised (Fig. 7). Postoperative improvement was spectacular. Fluid resuscitation and IV antibiotics continued on ICU. Histological examination of the paraffin sections confirmed the frozen section diagnosis of necrotising fasciitis showing furthermore acute inflammation, exten-

sive necrosis and hemosiderin deposits of the fascia lata. Blood cultures showed the presence of group A hemolytic streptococcus. Daily inspection of the wound under sedation showed no further extension of the necrotic process. After two negative wound swabs, split thickness skin grafts from the right thigh were used to cover the defect (day 12). Skin graft take was 100% (day 19) (Fig. 8). There were no further sequelae and the patient was discharged from hospital on day 22 in a good condition. Dressing changes and cauterization of hypertrophic granulation tissue between the skin grafts (Fig. 8) were performed on an outpatient basis. Intensive physio/kinesiotherapy helped the patient regain functionality and muscular strength of the lower limb (and avoided lymphedema of the lower leg and foot). He returned to his normal sports activities (football-amateur) one year later (Fig. 9). He has been followed for 7 years without pathological signs or need for readmission.

Discussion

Necrotising fasciitis (NF) is a rapidly progressive, destructive soft tissue infection with high mortality. There are four types of NF: Type I is polymicrobial with at least one anaerobic species with one or more facultative anaerobic streptococci and members of

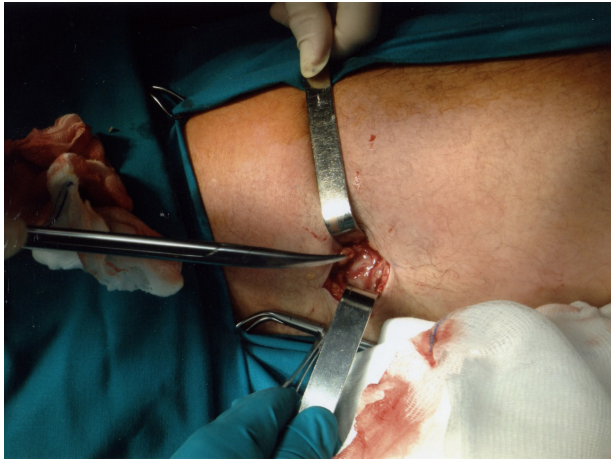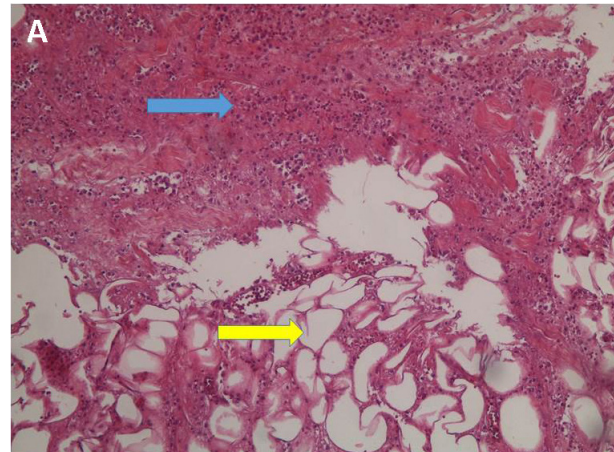


Fig.5. Incision through skin and subcutaneous tissue down to fascia. There was immediate flow of pus. The "finger-test" was positive.

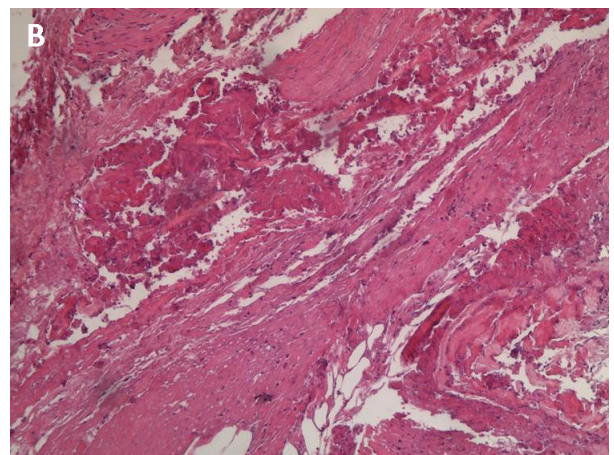
the enterobacteriaceae. Type II NF is a monobacterial infection caused by group A hemolytic streptococcus. Type III NF is caused by the marine *Vibrio* species. Type IV NF is caused by fungal cases of *Candida* and it is very rare (14).

The incidence of NF is low, 0.4 cases per 100,000 people (14). In the US, the annual age adjusted incidence was 4.3 invasive infections per 100,000 of the population (6). An increase, however, has been observed in Europe (UK), as well as in New Zealand. Brown et al (15) reported that the Health Protection Agency identified 1012 cases of invasive group A streptococcal infection (iGAS) between week 37, 2008 and week 20, 2009, compared to between 712 and 887 cases for the same period in the previous four years. Bodansky et al (16), in a more recent study reported that age-standardized incidence for NF patients requiring surgery increased from 4 to 20 per million across the study period (2002-2017). Das et al (17) observed a highly significant rise in annual incidence rates of NF in New Zealand from 0.18 to 1.69 per 100,000 person-years (1990-2006). Males seem to be more frequently affected than females (52.7% vs 47.3% - 11,042 patients) (16). The median age of patients is ca 60 years (range 44-60y) (16, 18).

In many cases of NF, an identifiable antecedent penetrating trauma or surgical procedure is evident. Surprisingly, the initial lesion can be often trivial, such as an insect bite, minor abrasion, boil,



- Necrobiotic tissue (blue arrow), dense infiltration of neutrophils.
- Fat necrosis (yellow arrow) (H&E stains X100)



fascial necrosis

H+E stains X100

Fig.6. A. Photomicrograph showing necrobiotic tissue (blue arrow), dense infiltration of neutrophils and fat necrosis (yellow arrow) (H&E stains x 100). **B.** Photomicrograph showing extensive fascial necrosis (H&E stains x 100).

postoperative infection or injection site (e.g., subcutaneous insulin, illicit drugs) (19). Cheung et al (6) reported that sites of prior trauma and skin lesions were the two most common portals of entry (44.8% of patients). Furthermore, these infections can develop secondarily to minor blunt trauma, muscle strain or even spontaneously. Spontaneous occurrence is rare, with hematogenous or lymphatic spread responsible for the translocation of group A β hemolytic *Streptococcus* (GAS) (15). Although a minor muscle injury cannot be excluded in the

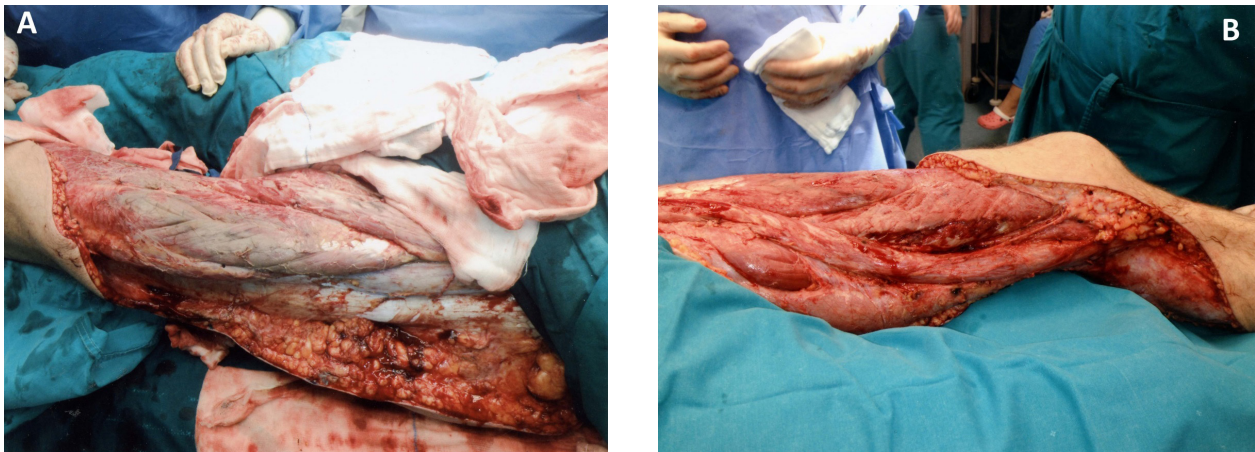


Fig.7 Patient two after surgical debridement. A. Lateral aspect. B. Medial aspect.

two patients presented here (gym, ski), no relevant symptoms were reported by either of them and no clinical signs indicative of a muscle injury could be identified. The most common presentation of GAS infection is with pharyngitis which accounts for up to 40% of cases seen by general practitioners in the United Kingdom (20). The majority of patients with NF, however, do not have preceding symptoms of pharyngitis or tonsillitis (21). The differences in severity of invasive streptococcal infections have been attributed to human leucocyte antigen class II allelic variation. This is due to their ability to regulate cytokine responses triggered by streptococcal super antigens (22). Both patients reported here had culture proven streptococcal pharyngitis which manifested a few days before onset of NF symptoms and signs. The latter were overlooked by general practitioners in both cases.

The clinical presentation of necrotising fasciitis entails progressive skin changes. Early on, only tenderness, erythema, warm skin and swelling are present, as was seen in both patients described here. Specific signs such as crepitus and blistering are rare. The average time of symptoms until hospital admission has been reported 4.1 days (8). In an American study on 198 patients, swelling was present in 75.0%, pain in 72.9%, and erythema in 66.3% (8). Foul discharge (46.8%), induration (45.3%), crepitus (36.5%), fever (31.6%), skin slough or necrosis (31.1%), blistering (23.7%), and skin discoloration (18.4%) occurred less frequently (8). In an

other study from India involving 75 patients, 91% presented with local tenderness, 99% with edema, 72% with erythema, 73% with ulceration and 72% with a purulent or serous discharge (23). Hypotension (systolic blood pressure < 90 mmHg) (see Case two) was reported in 11-33% (6, 8) and disorientation/mental obtundation in 17-24% (6, 8). At the initial stage, many patients are mistakenly diagnosed as having cellulitis due to overlapping diagnostic characteristics between cellulitis and NF. This results in delayed management. When critical skin ischemia occurs, blisters or bullae are formed. Blistering is due to ischemia-induced necrosis as the invading organisms cause progressive thrombosis of vessels that penetrate the fascia to supply skin (24). As the disease progresses, skin lesions turn black and form a necrotic crust. The occurrence of tissue necrosis results in hypo- or anesthesia of the affected region due to nerve involvement (6). Tissue crepitation may be present due to gas production by aerobic and anaerobic bacteria. The skin eventually becomes hemorrhagic and gangrenous (6).

Diagnosis of NF, especially of the initial stage, is difficult due to its similar clinical presentation with other skin and soft tissue infections. Initial suspicion, however, is based on the clinical picture. The presence of severe pain, fever and thigh skin erythema without underlying hip pathology raised strong suspicion of a necrotising infection in our first patient, whereas the entire clinical picture of our second patient was indicative of necrotising fasciitis,

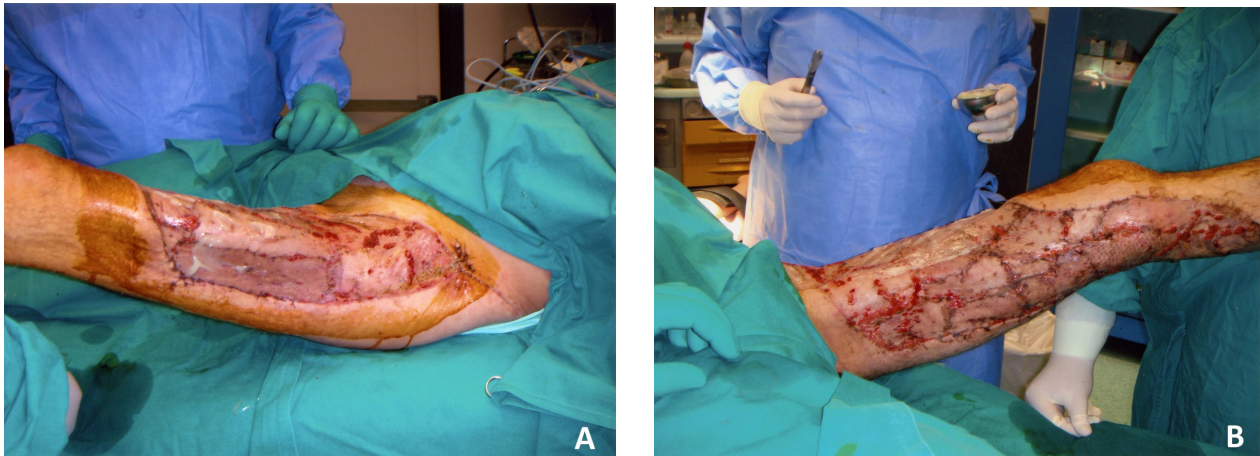


Fig.8. Patient two after skin grafting of left thigh defect. Hypertrophic granulation tissue is seen at graft junctions. A. Lateral aspect. B. Medial aspect.

despite the different opinion of the infections specialist. The Laboratory Risk Indicator for Necrotising Fasciitis (LRINEC: C-reactive protein, white cell count, hemoglobin, sodium, creatinine, and glucose) has been proposed as a diagnostic tool for NF infection (24). Patients with a LRINEC score of $>$ or $=$ 6 should be carefully evaluated for the presence of NF; a score of $>$ or $=$ 8 is strongly predictive of this disease. The value of LRINEC has been validated by later studies even for patients with comorbid conditions (25, 26, 27). Su et al (25) reported that patients with a LRINEC score of $>$ or $=$ 6 have a higher rate of both amputation and mortality. Other authors observed that severe hypoalbuminemia, severe thrombocytopenia and increased banded forms of leucocytes are laboratory risk indicators of NF and predict a higher risk of death (28). Recently, serum procalcitonin has been suggested as a useful marker for differentiating NF from cellulitis. A cut-off value of 1.0 had a sensitivity of 88%, a specificity of 89%, a positive predictive value of 81%, and a negative predictive value of 93% (29). The most useful diagnostic imaging modality in the diagnosis of NF is MRI. Signs that support a diagnosis of NF include extensive involvement of the deep intermuscular fasciae (high sensitivity, low specificity), thickening to more than 3 mm, and partial or complete absence on post-gadolinium images of signal enhancement of the thickened fasciae (fairly high sensitivity and specificity) (30). Ultrasonography is not recom-

mended in adults, as the infiltration of the hypodermis blocks ultrasound transmission (30). Imaging may help to confirm deep tissue involvement and to evaluate lesion spread, however, it should never delay emergency surgical treatment in patients in whom NF is strongly suspected (30, 31).

The “finger-test” and rapid frozen section biopsy examination have proved very useful in aiding diagnosis of patients presenting with suspected necrotising fasciitis in the early and intermediate stages (32, 33, 34). The test is performed in the following manner: the area of suspected involvement is infiltrated with local anesthesia and a 2-cm incision is made in the skin down to the deep fascia. Lack of bleeding is an ominous sign of a necrotising process. On many occasions, a “murky, dishwasher fluid” has been noted in the wound (clear pus in Case 2 of the present study). A gentle probing maneuver with the index finger is performed at the level of the deep fascia. If the tissues dissect with minimal resistance, the finger-test is positive. Tissue biopsies are sent for frozen section analysis. The characteristic histologic findings include obliterative vasculitis of the subcutaneous vessels, acute inflammation, and subcutaneous tissue necrosis (33). If the finger-test or the rapid frozen section analysis is positive or if the patient has progressive clinical findings consistent with NF, he/she should be resuscitated and taken emergently to the operating theatre for surgical debridement.

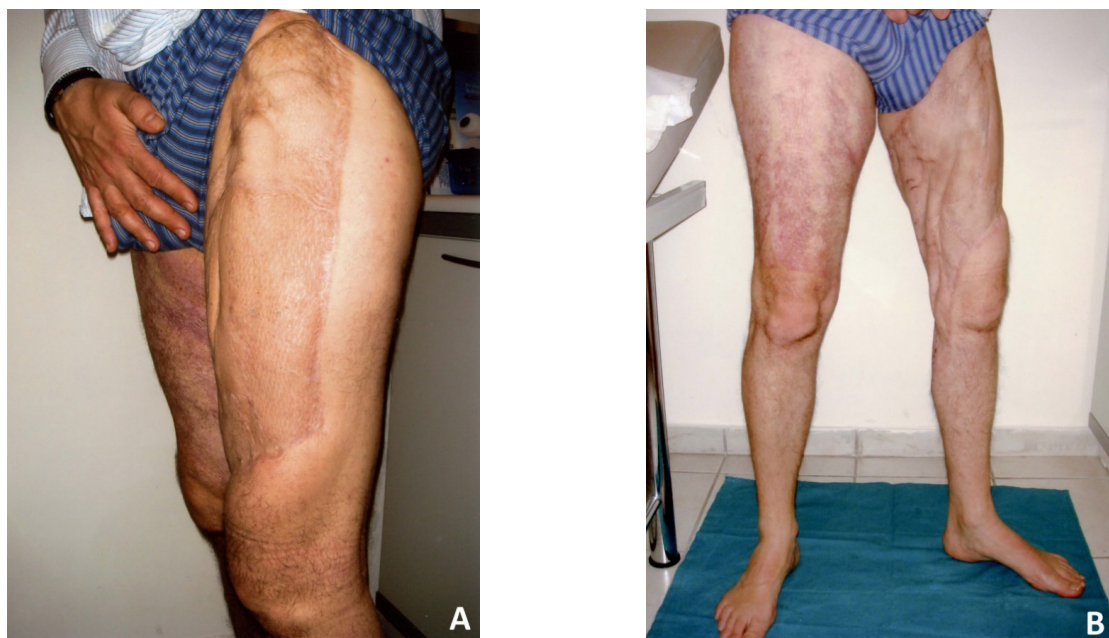


Fig.9. Patient two one year postoperatively. A. Lateral aspect. B. Medial aspect.

Necrotising fasciitis represents a surgical emergency. The large amount of necrotic tissue fuels a persistent septic state and recalcitrant hemodynamic instability. Whenever possible, aggressive resuscitation must be initiated immediately to maintain hemodynamic stability (19). However, one may not be able to completely stabilize the patient before surgery, in which case the anesthetist continues the resuscitative efforts intraoperatively (33). Surgical debridement of all obviously necrotic and poorly perfused tissues leads to more rapid overall clinical improvement. It is therefore essential that surgeons be consulted early in the care of these challenging patients. Early surgical debridement is a life-saving treatment (34, 35, 36). Furthermore, it may minimize tissue loss, eliminating the need for amputation of the extremity, which has been reported to be necessary in ca 22% of patients (6, 35, 36). There has been controversy regarding how much tissue should be initially excised because the skin may often appear normal. Andreasen et al (33) examined the normal-appearing tissues microscopically and found that they had extensive early vascular thrombosis and vasculitis, suggesting a high potential for full thickness loss. Therefore, these authors recommended wide, extensive debridement of all

tissues that can be easily elevated off the deep fascia with gentle finger dissection. The wound must be inspected closely (usually daily), as hemodynamic instability usually persists postoperatively, and progressive skin necrosis may occur from infectious spread or hypoperfusion, as was observed in Case one of this study. Further debridement as often as necessary should be performed until the patient is fully stabilized and all necrotic tissue is removed. Once all of the affected tissues have been debrided, on an average between one and four debridements are necessary (19), the patient is asymptomatic and two consecutive tissue cultures are negative, reconstruction of the defect should be considered. Skin autografts are the best option for larger defects, whereas small defects (< 200cm²) in difficult sites (e.g. articular surfaces) can be covered with free tissue transfer (37).

When there is limited donor-site availability, alternatives to standard skin graft reconstruction include collagen-chondroitin scaffold (Integra artificial skin - Integra Life Sciences, Plainsboro, NJ, USA) or decellularized human dermis (Alloderm - Lifecell Corporation, Blanchburg, NJ, USA) (33, 38) or any other of the currently available skin replacement technologies (39). Median time to grafting

has been reported 12 days (IQR 5 – 22) (40), which coincide with the time both our patients underwent the reconstructive procedure. One hundred percent graft take was observed in both patients and no further reconstructive procedures were necessary. Intense postoperative physical/kinesiotherapy enabled both patients to return to normal physical activities (walking, etc.-three months) and sports (six to eight months) after hospital discharge.

Irreversible necrotic changes following sepsis and failed multiple debridements necessitate limb amputation (6). In a recent Danish nationwide register – based cohort study, amputation occurred in 7% of the individuals (41). Khamnuan et al (42) reported a similar amputation rate (8.4% - 127/1,507 patients) in a study from Thailand. Predictive factors for amputation included gangrene (risk ratio RR 4.77), diabetes mellitus (RR 3.08), skin necrosis (RR 2.83), soft tissue swelling (RR 1.76), and serum creatinine values > 1.6 mg/dL on admission (RR 1.71). Another recent cohort multicenter prospective study from Scandinavia reported that amputation occurred in 22% of patients with NF of an extremity and was associated with higher lactate level (43). Horn et al (36) analyzed prospectively 446 patients with surgically confirmed NF. Twenty one percent of extremity NF patients required amputation. Age greater than 60 years, male sex, nonwhite race, diabetes, chronic wound as etiology, leg involvement, transfer status, and sodium < 130 mEq/L were independently associated with amputation. Patients with any of the above predictors should be monitored for progression and receive early aggressive treatment to avoid limb loss (36).

Immediate postoperative care is provided in the critical care setting. Fluid resuscitation, antibiotic therapy and nutritional support form an essential part of the postsurgical patient care. After the bacteria have been identified, therapy can usually be tailored further. Antibiotic therapy for necrotising infections in particular has not been studied in randomized controlled trials (44). The Surgical Infection Society and Infectious Disease Society of America guidelines both strongly recommend combination therapy with penicillin and clindamycin in necrotising soft tissue infections due to GAS (45, 46). No

clinical trials have evaluated duration of therapy in NF (47). Guidelines suggest continuation of appropriate antibiotics for a minimum of 48 – 72 h after resolution of fever and other systemic signs of infection as well as hemodynamic stabilization (47).

Adjunctive medical treatments for NF have been utilized, the most common of which include intravenous immune globulin (IVIG) and hyperbaric oxygen. The proposed mechanism of action of IVIG relates to binding and inactivating circulating superantigens, thereby blunting the superantigen-mediated cytokine cascade. A propensity-matched analysis of administrative data from 130 US hospitals (48) and a RCT from Denmark (INSTINCT study) (49) found no benefit of IVIG on physical functioning or survival at 6 months. Hyperbaric oxygen is believed to potentially enhance oxygen delivery to hypoxic tissues surrounding areas of necrosis, directly killing anaerobic bacteria and improving leucocyte activity (50). Encouraging results were reported by Jallali et al (50), however, a more recent systematic literature review failed to locate relevant clinical evidence to support or refute the effectiveness of hyperbaric oxygen therapy in the management of necrotising fasciitis (51). Furthermore, the greatest barrier to practical use of hyperbaric oxygen in NF is the limited number of centers with hyperbaric chambers where critically ill patients can be adequately monitored (47).

Despite efforts to treat the rapid infective process, many patients still die through complications of sepsis (pneumonia, heart failure, metabolic disturbance) and finally multiorgan failure (6). It should be noted, however, that mortality rates, reported as high as 75% two decades ago (6), have been mitigated and currently range between 15 and 20% (18, 36, 40, 41, 42, 43). In a study of the US Multiple Cause of Death files (2003 – 2013), 9,781 NF – related deaths were identified corresponding to a crude mortality rate of 4.8 deaths/1,000,000 person – years. Diabetes mellitus, obesity and renal failure were significantly associated with NF-related death (52). Fatal cases of NF were more common among older individuals, and the greatest number of cases was observed among individuals aged 55 to 64 years (52). In another study, Ahn et al (53)


reviewed retrospectively the American College of Surgeons – National Surgical Quality Improvement Program and found 674 patients with lower extremity NF. Although diabetes mellitus (DM) was associated with more amputations for lower extremity NF, patients with DM had lower mortality than non – DM patients in the bivariate analysis (53). Increased mortality has been associated with age > 60 years by most authors (34, 36, 41, 42, 43, 53). Other factors which have been associated with a higher mortality rate include higher lactate level (43), white blood cell count > 30×10^2 /ml and platelets < 150×10^3 /ml (36), systolic blood pressure < 90 mmHg and serum creatinine > 1.6 mg/dL (42), partial thromboplastin time > 38 seconds, and albumin > 2.0 mg/dL (53). Comorbid conditions (congestive heart failure, peripheral vascular disease, chronic kidney disease and cancer) were associated with higher in-hospital mortality (34, 40). Mortality rate has been shown to increase when patients are transferred from outside facilities (18), whereas admission to high-volume hospitals seem to be associated with improved survival (41).

The severity of NF and the aggressive treatment requirements put survivors at risk for significant long-term sequelae related to the trauma of both disease and treatment. While mortality rates have improved, long-term outcomes in survivors are poorly understood (54). Patients who have survived often suffer from functional impairment and altered body appearance. Pain medication and/or supportive devices are frequently required and the patients present with significant physical, psychological and relational sequelae at midterm follow-up (55). Hakkarainen et al (56) interviewed 18 NF survivors with a median follow-up of 4.2 years (range 3-6y) and identified increased value placed on life, some level of depression (related to external disfigurement), posttraumatic stress, pain, sexual difficulties, physical function (loss of mobility), behavioral changes, fear of infection, change in dress, and change in social activities (e.g., dance due to physical impairment). Both our patients initially reported fear of infection, temporary relational difficulties, and influenced societal factors, all of which were normalized at long term follow-up. Special atten-

tion which had been given to the reconstructive part of their treatment, and intensive active and passive physical therapy resulted in an acceptable appearance of the limb and near normal functionality (no oedema, ROM, muscular strength etc.) one year after hospital discharge.

The presentation of two cases of streptococcal pharyngitis and ensuing NF of the lower limb, no matter how rare, aims to alert clinicians to a high index of suspicion for necrotising fasciitis, which has an aggressive clinical course and can progress rapidly (within hours). Clinicians should have a high index of suspicion and a low threshold for surgical referral (11). Complaints of pain out of proportion to the visible findings or excruciating tenderness are clinical aids to early diagnosis. Upon admission, the general approach is to start empirical antibiotics, as most conditions will respond. Repeated physical examinations should be performed whilst maintaining a low threshold for a “finger test”, tissue biopsy and surgery. It is safer to treat the ambiguous cases as necrotising fasciitis and manage them aggressively, as delay in treatment can be life threatening.

Conclusions

Streptococcal pharyngitis can, very seldom, lead to necrotizing fasciitis/myositis of the lower limb. Because of the potentially fatal course of NF, early diagnosis is the key to a favorable outcome. Laboratory findings (LRINEC score) and imaging may be useful, however, the diagnosis is a clinical one, and suspicion alone warrants early surgical consultation. The mainstay of treatment is immediate resuscitation of the patient, followed by aggressive surgical debridement and intravenous antibiotic therapy. Once the patient's condition has been stabilized, meticulous reconstruction of the defect followed by intensive physiotherapy is mandatory in order to ensure a better postoperative quality of life. 

Acknowledgement

The authors are grateful to Dr. Lydia Abu – Asabe for the preparation of the photomicrographs.

Conflict of interest

No conflict of interest to declare.

REFERENCES

1. Ozalay M, Ozcoc G, Akpınar S et al. Necrotizing soft-tissue infection of a limb: Clinical presentation and factors related to mortality. *Foot & Ankle Internat* 2006; 27: 598-605
2. Bilton BD, Zibari GB, McMillan RW et al. Aggressive surgical management of necrotizing fasciitis serves to decrease mortality: a retrospective study. *Am Surg* 1998; 64: 397-400; Discussion 400-1
3. Wilson BL. Necrotizing fasciitis. *Am Surg* 1952; 18: 416-31
4. Wallace HA, Perera TB. Necrotizing fasciitis. In: *Stat Pearls* [Internet]. Treasure Island (FL): Stat Pearls Publishing, 2020
5. May AK, Talisa VB, Wilfret DA et al. Estimating the impact of necrotizing soft tissue infections in the United States: Incidence and re-admissions. *Surg Infect (Larchmt)* 2020; doi:10.1089/sur.2020.099
6. Cheung JP, Fung B, Tang WM et al. A review of necrotizing fasciitis in the extremities. *Hong Kong Med J* 2009; 15: 44-52
7. Widjaja AB, Tran A, Cleland H et al. The hospital costs of treating necrotizing fasciitis. *ANZ J Surg* 2005; 75: 1059-64
8. Elliott DC, Kufera JA, Myers RAM. Necrotizing soft tissue infections: Risk factors for mortality and strategies for management. *Ann Surg* 1996; 224: 672-83
9. Rantala S, Vuopio-Varkila J, Vuento R et al. Predictors of mortality in beta - hemolytic streptococcal bacteremia: A population - based study. *J Infect* 2009; 58: 266-72
10. Ioannidis Ch. Necrotising fasciitis after cesarean section. *HJOG* 2013; 12: 63-7
11. Hasham S, Matteucci P, Stanley PRW et al. Necrotising fasciitis. *BMJ* 2005; 330: 830-3
12. Whallett EJ, Stevenson JH, Wilmhurst AD. Necrotising fasciitis of the extremity. *J Plast Reconstr Aesthet Surg* 2010; 63: e469-73
13. Wong CH, Wang YS. The diagnosis of necrotising fasciitis. *Curr Opin Infect Dis* 2005; 18: 101-6
14. v Sambeek CHL, v Stigt SF, Browsers L et al. Necrotising fasciitis: a ticking time bomb? *BMJ Case Rep* 2017; bcr 2017 221770
15. Brown CN, Pollard TCB, Iyer S et al. Invasive group A streptococcal infection. *J Bone Joint Surg (Br)* 2010; 92: 763-9
16. Bodansky DMS, Begaj I, Evison F et al. A 16-year longitudinal cohort study of incidence and bacteriology of necrotising fasciitis in England. *World J Surg* 2020; 44: 2580-91
17. Das DK, Baker MG, Venugopal K. Increasing incidence of necrotizing fasciitis in New Zealand: a nationwide study over the period 1990 to 2006. *J Infect* 2011; 63: 429-33
18. Faraklas I, Yang D, Eggerstedt M et al. A multi - center review of care patterns and outcomes in necrotizing soft tissue infections. *Surg Infect (Larchmt)* 2016; 17: 773-8
19. Edlich RF, Cross CL, Dahlstrom JJ et al. Modern concepts on the diagnosis and treatment of necrotizing fasciitis. *J Emerg Med* 2010; 39: 261-5
20. Dobbs F. A scoring system for predicting group A streptococcal throat infection. *Br J Gen Pract* 1996; 46: 461-4
21. Martin PR, Høiby EA. Streptococcal serogroup A epidemic in Norway 1987-1988. *Scand J Infect Dis* 1990; 22: 421-9
22. Kotb M, Norby - Jeglund A, McGeer A et al. An immunogenetic and molecular basis for differences in outcomes of invasive group A streptococcal infections. *Nat Med* 2002; 8: 366-71
23. Singh G, Sinha SK, Adhikary S et al. Necrotizing infections of soft tissues - a clinical profile. *Eur J Surg* 2002; 168: 366-71
24. Wong CH, Khin LW, Heng KS et al. The LRINEC (Laboratory Risk Indicator for Necrotizing fasciitis) score: a tool for distinguishing necrotizing fasciitis from other soft tissue infections. *Crit Care Med* 2004; 32: 1535-41
25. Su YC, Chen HW, Hong YC et al. Laboratory risk indicator for necrotizing fasciitis score and the outcomes. *ANZ J Surg* 2008; 78: 968-72
26. Bechar J, Sepheiripour S, Hardwicke J et al. Laboratory Risk Indicator for necrotizing fasciitis (LRINEC) score for the assessment of early necrotizing fasciitis: a systematic review of the literature. *Ann*

- R Coll Surg Engl 2017; 99: 341-46
27. Henry R, Matsushima K, Etzel M et al. Utility of the Laboratory Risk Indicator for Necrotizing Fasciitis Score: Comorbid conditions do matter. *Surg Infect (Larchmt)* 2021. doi: 10.1089/sur.2020.398
 28. Tsai YH, Hsu RW, Huang KC et al. Laboratory indicators for early detection and surgical treatment of vibrio necrotizing fasciitis. *Clin Orthop Relat Res* 2010; 468: 2230-7
 29. Kishino T, Asai N, Okashi W et al. Usefulness of serum procalcitonin for necrotizing fasciitis as an early diagnostic tool. *J Infect Chemother* 2021; S1341-321X (21)00003-9
 30. Malghem J, Lecouvet FE, Omoumi P et al. Necrotizing fasciitis: contribution and limitations of diagnostic imaging. *Joint Bone Spine* 2013; 80: 146-54
 31. Kim MC, Kim S, Cho EB et al. Utility of magnetic resonance imaging for differentiating necrotizing fasciitis from severe cellulitis: A magnetic resonance indicator for necrotizing fasciitis (MRINEC) algorithm. *J Clin Med* 2020; 9: 3040. doi: 10.3390/jcm9093040
 32. Stamenkovic I, Lew PD. Early recognition of potentially fatal necrotizing fasciitis. The use of frozen-section biopsy. *N Engl J Med* 1984; 310: 1689-93
 33. Andreasen TJ, Green SD, Childers BJ. Massive infectious soft-tissue injury: diagnosis and management of necrotizing fasciitis and purpura fulminans. *Plast Reconstr Surg* 2001; 107: 1025-34
 34. Childers BJ, Potyondy LD, Nachreiner R et al. Necrotizing fasciitis: a fourteen-year retrospective study of 163 consecutive patients. *Am Surg* 2002; 68: 109-16
 35. Carter PS, Banwell PE. Necrotizing fasciitis: a new management algorithm based on clinical classification. *Int Wound J* 2004; 1: 189-97
 36. Horn DL, Shen J, Roberts E et al. Predictors of mortality, limb loss, and discharge disposition at admission among patients with necrotizing skin and soft tissue infections. *J Trauma Acute Care Surg* 2020; 89: 186-91
 37. Gawaziuk JP, Liu T, Sigurdson L et al. Free tissue transfer for necrotizing fasciitis reconstruction: a case series. *Burns* 2017; 43: 1561-66
 38. Frame JD, Still J, Lakhel – LeCoadou A et al. Use of dermal regeneration template in contracture release procedures: a multicenter evaluation. *Plast Reconstr Surg* 2004; 113: 1330-8
 39. Klimov M, Panayi A, Borah G et al. The life – cycles of skin replacement technologies. *PLoS One* 2020; 15: e0229455
 40. Bodansky DMS, Begaj I, Evison F et al. A 16-year longitudinal cohort study of incidence and bacteriology of necrotizing fasciitis in England. *World J Surg* 2020; 44: 2580-91
 41. Hedetoft M, Madsen MB, Madsen LB et al. Incidence, comorbidity and mortality in patients with necrotizing soft- tissue infections, 2005-2018: a Danish nationwide register-based cohort study. *BMJ Open* 2020; 10: e041302
 42. Khamnuan P, Chongruksut W, Jearwattananok K et al. Necrotizing fasciitis: epidemiology and clinical predictors of amputation. *Int J Gen Med* 2015; 8: 195-202
 43. Madsen MB, Skrede S, Perner A et al. Patients' characteristics and outcomes in necrotizing soft-tissue infections: results from a Scandinavian, multicenter, prospective cohort study. *Intensive care med* 2019; 45: 1241-51
 44. Hua C, Bose R, Sbidian E et al. Interventions for necrotizing soft tissue infections in adults. *Cochrane Database Syst Rev* 2018; 5: CD011680
 45. May AK, Stafford RE, Bulger EM et al. Surgical Infection Society. *Surg Infect (Larchmt)* 2009; 10: 467-99
 46. Stevens DL, Bisno AL, Chambers HF et al. Practice guidelines for the diagnosis and management of skin and soft tissue infections. 2014 Update by the Infectious Diseases Society of America. *Clin Infect Dis* 2014; 59: 147-59
 47. Bonne S, Kadri SS. Evaluation and management of necrotizing soft tissue infections. *Infect Dis Clin North Am* 2017; 31: 497-511
 48. Kadri SS, Swihart BJ, Bonne SL et al. Impact of intravenous immunoglobulin on survival in necrotizing fasciitis with vasopressor – dependent shock: A propensity – score matched analysis from 130 US hospitals. *Clin Infect Dis* 2017; 64: 877-85

49. Madsen MB, Hjortrup PB, Hansen MB et al. Immunoglobulin G for patients with necrotizing soft tissue infection (INSTINCT): a randomized, blinded, placebo - controlled trial. *Intensive Care Med* 2017; 43: 1585-93
50. Jallali N, Withey S, Butler PE: Hyperbaric oxygen as adjuvant therapy in the management of necrotizing fasciitis. *Am J Surg* 2005; 189: 462-6
51. Levett D, Bennett MH, Millar I: Adjunctive hyperbaric oxygen for necrotizing fasciitis. *Cochrane Database Syst Rev* 2015; 1: CD007937
52. Arif N, Yousfi S, Vinnard C. Deaths from necrotizing fasciitis in the United States, 2003-2013. *Epidemiol Infect* 2016; 144: 1338-44
53. Ahn J, Raspovic KM, Liu GT et al. Lower extremity necrotizing fasciitis in diabetic and non-diabetic patients: Mortality and amputation. *Int J Low Extrem Wounds* 2019; 18: 114-21
54. Gawaziuk JP, Strazar R, Cristall N et al. Factors predicting health-related quality of life following necrotizing fasciitis. *J Plast Reconstr Aesthet Surg* 2018; 71: 857-62
55. Kruppa C, Hutter DJ, Königshausen M et al. necrotizing fasciitis and the midterm outcomes after survival. *SAGE Open Med* 2019; 7: 2050312119842433
56. Hakkarainen TW, Ikebata NB, Bulger E et al: Moving beyond survival as a measure of success: understanding the patient experience of necrotizing soft - tissue infections. *J Surg Res* 2014; 192: 143-9

READY - MADE
CITATION

Ch Ioannidis, B Cohen, S Giannacopoulou, P Alevras. Necrotising fasciitis of the lower extremity following streptococcal pharyngitis. *Acta Orthop Trauma Hell* 2022; 73(2): 166-179.