

# Cervical sagittal balance after AIS instrumentation

Ali Asma<sup>1</sup>, Haluk Berk<sup>2</sup>

<sup>1</sup>Nemours Alfred I. duPont Hospital, Department of Orthopedic Surgery  
Wilmington, Delaware

<sup>2</sup>Department of Orthopedic Surgery, Dokuz Eylul University, Izmir, Turkey  
haluk.berk58@gmail.com

## ABSTRACT

Cervical sagittal balance is one of the trending topics in the literatures. More than 60 articles were published on this hot topic. The harmonious relationship between spinal curves and kyphotic deterioration proximal to instrumentation made the researchers' main intentions. Most authors investigate the changes in cervical sagittal curves after AIS instrumentation and look for any correlation between the sagittal parameter that could hint at potential changes after instrumentation. Some authors look into the upper instrumentation level effect on cervical alignment others searched for coronal plane deformities effect on the sagittal plane. Prospective studies will be more convincing since retrospective studies show the opposite results. A meta-analysis of future prospective studies will clarify the confusion on upper instrumentation level effect on CSB, implant choice of instrumentation, PJK reasons, correlation with global spine balance, and finally, relationship with whole-body alignment. Correction of thoracic hypokyphosis, especially proximal thoracic, could stimulate cervical lordotic changes over time. Flattening of the entire spine either by surgery or bracing ends up with cervical kyphosis. In this updated historical review of cervical sagittal balance after AIS instrumentation, we want to report the most current and organized knowledge of this exciting area of the spine studies. To make it more systematic, we subdivide primary theme into six main sections to answer all the potential questions of the readers. While giving essential information about cervical sagittal balance, we also delve into details to clarify this very confusing area.

**KEY WORDS:** Scoliosis, cervical sagittal balance, spinal instrumentation

### Introduction

Cervical sagittal balance is under the scope of spine authors in the last decade after well understanding the sagittal plane on AIS patients' overall quality of life. More than 60 articles were published on this hot topic. The harmonious relationship between spinal curves and kyphotic deterioration proximal to in-

strumentation made the researchers' main intentions. Most authors investigate the changes in cervical sagittal curves after AIS instrumentation and look for any correlation between the sagittal parameter that could hint at potential changes after instrumentation. Some authors look into the upper instrumentation level effect on cervical alignment others

CORRESPONDING  
AUTHOR,  
GUARANTOR

Ali Asma, Md  
Alfred I DuPont Hospital  
1600 Rockland Rd, Wilmington, DE 19803, Phone: (302) 390 1298, Work Phone:  
(302) 651 5837, Email: ali.asma@nemours.org

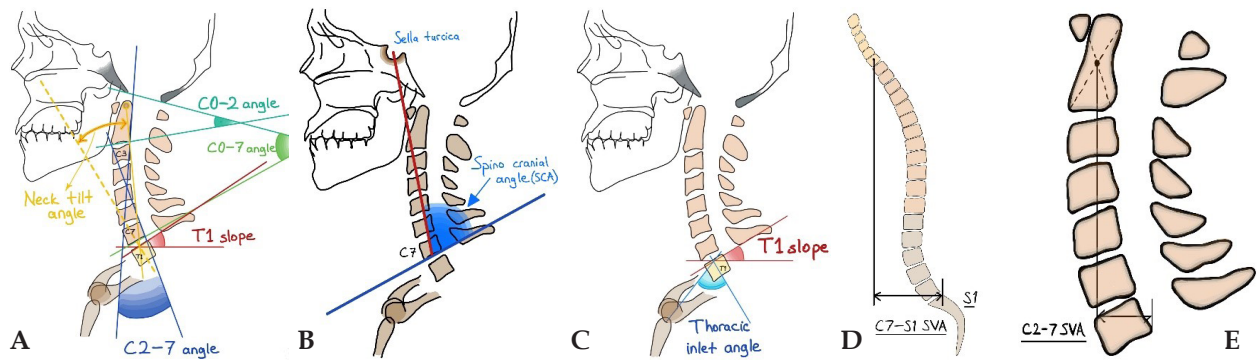


Figure 1 A,B,C,D,E. Cervical and Global Sagittal Parameters

searched for coronal plane deformities effect on the sagittal plane. This review will delve into the most recent knowledge of Cervical Sagittal Balance(CSB) after AIS instrumentation.

## Discussion

### 1. Defining Cervical Sagittal Balance

Cervical sagittal balance is a term used to define the cervical vertebral segment's actual position over the rest of the spine and its relation with the cranium. It is known that cervical mechanisms have an essential role in the compensation of pelvic and global spinal changes. The cervical spinal segment's role in global spinal balance was underestimated previously due to the sagittal vertical axis (SVA) measurement through the C7 vertebral body. CSB is a collection of measurement parameters for sagittal plane alignment. These consist of C0-C7 sagittal vertical axis (SVA), C2-C7 SVA, T1 Slope, Chin Brow Vertical Angle (CBVA), Thoracic Inlet Angle (TIA), Spino Cranial Angle (SCA) Head Tilt, Neck Tilt and other numerous parameters that published in every separate article(1). SCA is an angle between a line from cella turcica to C7 upper endplate and a line tangential to this endplate. It gives an impression about head offset over cervicothoracic transition(2).

For C2-C7 SVA, the distance from the vertical plumb line drawn from the C2 vertebral body to the C7 vertebra posteroinferior corner is measured, and >4 cm is accepted as abnormal (3). It is shown that abnormal C2-C7 measurement is related to low health-related quality of life scores (4). For the T1 slope, the angle between the T1 vertebra upper-end plate line and the horizontal reference line is measured.

(Fig 1) The increase in the T1 slope can be seen after thoracic hyperkyphosis, or it can be secondary to a positive global balance by an increase in the anterior tilt of the body. The increase in the T1 slope is compensated by cervical lordosis enhancement to maintain a horizontal gaze. However, sometimes if decompensation involves the cervicothoracic region, pelvic retroversion can take the role to maintain a horizontal gaze. The preliminary results of an ongoing study from our clinic showed that the T1 vertebra plays a keystone role for the whole spine as it is correlated with LCL, T5-T12K, SVA, and C2-C7SVA. According to a recent systematic review, the most important parameters to study the cervical sagittal balance as stated by the literature for good clinical outcomes are the following: C7 or T1 slope, average value 20°, must not be higher than 40°, SVA must not be less than 40mm (mean value 20 mm), and SCA (spine cranial angle) must stay in a norm ( $83^\circ \pm 9^\circ$ )(1). A recent meta-analysis showed that the T1 slope has the most potent correlation with cervical lordosis(5). Thoracic kyphosis and cervical lordosis correlation were moderate, but the correlation between CL and lumbar lordosis and other pelvic parameters was weak.

### 2. Relationship with global spine

To understand the CSB relationship with spinal alignment and its role in global balance, we should first understand the transitions of spinal curvatures and different types of whole spine sagittal alignment. Thanks to Kariman et al., they filled the gap in Lenke Classification by introducing a sagittal plane classification. (6) New classification based on the

sagittal profile of spine which includes Type 1 with normal sagittal alignment (standard TK, straight thoracolumbar transition and standard LL), Type 2a with thoracic hypokyphosis, Type 2b with thoracic hypokyphosis+thoracolumbar kyphosis, and Type 3 with cervicothoracic kyphosis + thoracolumbar lordosis. They claimed that this classification would guide surgical treatment to create a normal sagittal contour for each curve type, such as in Type2b, the correction of thoracic hypokyphosis, and flattening thoracolumbar transition or in Type 3 to lower the inflexion point from upper levels to its normal corresponding thoracolumbar level. They also did a 3d validation for this new classification system, which showed only the type 3 group has a variation in the TL angle compared to 2dEOS due to increased thoracolumbar lordosis in this group.

Cervical spinal balance (CSB) and global spinal balance (GSB) have a mutual relationship. An increase in PI can increase lumbar lordosis, which causes an increase in thoracic kyphosis secondarily and cervical lordosis tertiary(7). On the other hand, the decrease in lumbar lordosis causes pelvic retroversion and positive SVA, increasing cervical lordosis. If spinal deformity originates from the cervical region as in increased cervical kyphosis, pelvic retroversion is increased to supply enough pelvic tilt to maintain a horizontal gaze. Contrary to common belief, the increase in lumbar lordosis accompanies the pelvic tilt increase in this situation where the deformity originated from the cervical region rather than the lumbar region.

T1 pelvic angle is a valuable parameter of CSB, which is the intersection of two lines; one started from the T1 vertebra to the bifemoral head center, and the other started from the S1 vertebra upper-end plate center to the bifemoral head center. It is valuable due to being cleared from pelvic compensation or positional changes (8).

Moreira et al. showed that proximal thoracic kyphosis is the defining factor for cervical spine sagittal alignment. It is a similar relationship between proximal lumbar lordosis and thoracic kyphosis. (9) Akbar et al.(10) showed that upper cervical and cranial parameters were not statistically different in their study groups, including hypokyphotic and

normokyphotic populations, which shows that the upper cervical spine was not recruited for compensation in order to maintain a horizontal gaze. In contribution to this, Pepke et al.(11) showed that after AIS surgery, cervical curvature is influenced by TK, T1 Slope, and SVA and has changes in the lower cervical spine and no effect seen on the upper cervical spine.

In another study concentrated on the sagittal profile of the AIS population, Ito et al. (12) divided the AIS population according to their cervical lordosis  $>4^\circ$ , cervical kyphosis  $< -4^\circ$ , and sigmoid (one segment kyphotic and one segment lordotic) cervical alignment. They further divide cervical kyphosis groups into CK H where TK apex is above T4, CK m where TK apex is between T4-T9, and CK L where TK apex is below T9 level. They claimed that the CK H group is a compensation cervical kyphosis for the relatively hypokyphotic thoracic region. Hilibrand et al. (13) showed that the AIS population's cervical kyphosis angle is  $6\pm 11^\circ$ . When they further divided this population according to the TK level, they realized postoperatively an increase in cervical kyphosis degree in normokyphotic or hyperkyphotic patients where an improvement into lordosis was seen in the hypokyphotic group. Although postoperative TK was in normal limits in preoperatively normo and hyperkyphotic groups, a tendency to postoperative cervical kyphosis is apparent in the AIS population. We have similar results in our ongoing research. Hypokyphotic thoracic spine has a better response in sagittal plane recreation compared to normo or hyperkyphotic thoracic spine.

It is known that thoracic alignment affects sagittal alignment inevitably. T6-T12 thoracic vertebrae are responsible for %10 of cervical movement(14). It is normal to anticipate that cervical lordosis will improve after the correction of thoracic hypokyphosis. However, Canavese et al.(15) found out that cervical alignment was not affected by thoracic kyphosis, even was not affected by the upper instrumentation level. They attributed these results to the ongoing rigidification of cervical vertebrae with age. These results were different from the rest of the literature.

An article from Shimizu et al. (16) investigates

whole body sagittal alignment after thoracic instrumentation in the AIS population. They found out previously published data of reciprocal improvement of lordotic curves of the spine in response to thoracic curve correction. Interestingly they did not find any change in lower extremity sagittal alignment after TK instrumentation. However, they noticed a correlation between TK instrumentation change and knee flexion angle change, which indicates that iatrogenic inadequate alignment change in the thoracic curve could prompt knee alignment change as a compensatory mechanism.

The brace treatment also has an impact on cervical alignment. Thoracic pads' pressure to correct coronal plane curvature and rib convexity has a hypokyphotic effect on the thoracic spine. It causes a flat spine with decreased sagittal curves of lumbar lordosis, thoracic kyphosis, and cervical lordosis.(17) The authors also showed that the thoracic anteroposterior diameters declined after two-year bracing, which may result from reduced TK and contribute to further pulmonary function impairment.

### 3. Upper Instrumentation Level

It is the literature that shows that upper instrumentation does not affect cervical alignment, and it has. That is why it should be clarified with future prospective studies and later meta-analysis of these studies. In a study investigating the effect of the upper instrumented vertebra level on cervical sagittal alignment in Lenke 1 adolescent idiopathic scoliosis, the authors reported that T2-T3 instrumentation has a kyphotic effect on cervical lordosis, cause diminishing of T1 slope and T1-T5 kyphosis while T5-T12 kyphosis was not affected(18). In contrast to this, Zhao et al. showed no relation between cervical kyphosis and upper instrumented vertebra in a study to investigate the effect of instrumentation of T2, T3, and T4 on the cervical spine of Lenke 1 AIS patients. Both groups were Lenke 1 AIS (19)

The only comparative study in instrumentation comparison Legaretta et al(20) also mentioned upper instrumentation level effect on cervical alignment. They showed that in either pedicle screw construct or hybrid techniques, the patients with upper-instrumented vertebra at T4 or below showed

a lordotic effect that was more evident in the hybrid constructs ( $+9.4^\circ \pm 11.3$  vs.  $+0.3^\circ \pm 11.4$ ). In those with the upper-instrumented vertebra at T3 or higher levels, both techniques had a kyphotic effect that was more severe in the patients of the pedicle screws group ( $-7.0^\circ \pm 12.6$  vs.  $-2.8^\circ \pm 10.5$ ).

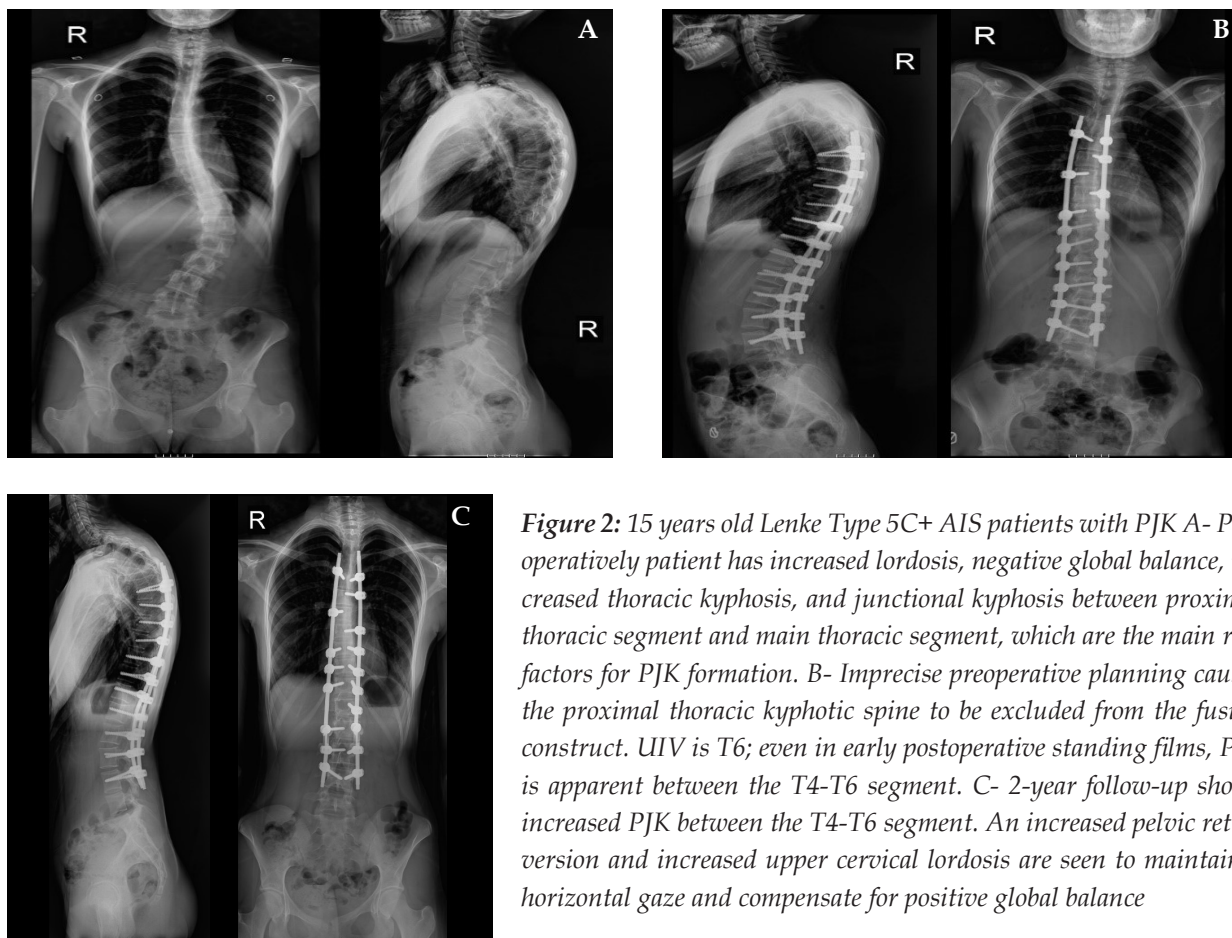
For Lenke type 3c and 6c curves where extensive fusions are needed to the proximal thorax, UIV level of T2, T3, T4 options did not significantly affect the absolute outcome of cervical kyphosis. It is essential to see that T5-T12 kyphosis has the primary responsibility in decreasing cervical lordosis; neither T1-T5 kyphosis nor upper instrumented vertebra could affect cervical kyphosis in this group(21). It makes it logical to choose UIV regarding to shoulder imbalance without an increased risk of cervical kyphosis. This is different from lenke 1 curves at where T2-T3 instrumentation has a significant kyphotic effect where T4 is spared(18). We also see in our cohort that T2 instrumentation has a kyphotic effect in lower cervical alignment, and most of the patients are in Lenke 1 group.

### 4. Proximal Junctional Kyphosis

Proximal Junctional Kyphosis is described as an increase of more than  $10^\circ$  of the sagittal Cobb angle between the inferior endplate of the upper instrumented vertebra and the superior endplate of two vertebrae above between pre and postoperative measurements. PJK is not a complication only specific to the adult degenerative spine. (Fig 2) The etiology is multifactorial, and many risk factors have been described. One of them is the disruption of musculo-ligamentous and bony tissues above the UIV during surgery. If the elaboration of structural curves, especially on the sagittal plane done negligently, the fixation level could end up with C2 instrumentation(22). So it is crucial in an adolescent deformity that adequate preoperative planning, including clinical and radiological study, must be carried out, paying particular attention to the sagittal plane to identify major and minor structural curves.

Sun et al. (23) showed in thoracolumbar/lumbar AIS population that the location of the lower instrumented vertebra (LIV) above or equal to L3, a higher postoperative lumbar lordosis (LL), and a backward





**Figure 2:** 15 years old Lenke Type 5C+ AIS patients with PJK A- Pre-operatively patient has increased lordosis, negative global balance, increased thoracic kyphosis, and junctional kyphosis between proximal thoracic segment and main thoracic segment, which are the main risk factors for PJK formation. B- Imprecise preoperative planning causes the proximal thoracic kyphotic spine to be excluded from the fusion construct. UIV is T6; even in early postoperative standing films, PJK is apparent between the T4-T6 segment. C- 2-year follow-up shows increased PJK between the T4-T6 segment. An increased pelvic retroversion and increased upper cervical lordosis are seen to maintain a horizontal gaze and compensate for positive global balance

change of SVA postoperatively were potential risk factors for the occurrence of PJK. Although we have not seen PJK in our cases if LIV is chosen as L2 or above it, we saw an increase in upper cervical lordosis to maintain horizontal gaze. We interpreted this as a compensation positive sagittal balance.

The position of UIV seems to be predictive in future sagittal alignment, basically through a proximal junctional angle (PJA). A larger anterior shift of the UIV in first erect X-ray relative to preop is highly related to PJK, affecting cervical sagittal alignment(24).

Ferrero et al.(25) investigate the risk factor for postoperative cervical decompensation in AIS. Fifty-seven patients have proximal junctional kyphosis (PJK) in 365 Lenke type 1 and type 2 groups. In patients with PJK preoperative PI, LL and C7 slope were significantly higher than the others. Postoperatively in this group, thoracic kyphosis did not change, the C7 slope decreased, and LL increased.

The inflection point that resembles lumbar lordosis's transition to thoracic kyphosis is also located in more upper segments postoperatively. In patients without PJK, postoperative TK increased, LL did not change. In conclusion, the authors declared that increased lumbar lordosis (that causes posteriorly located negative spinal balance), insufficient compensation of thoracic segments to increased lordosis, and superior location of inflexion point make three risk factors for postoperative PJK in the AIS population.

Ghailane et al.(26) reported on the effect of hybrid construct on PJK, and they showed that no increase in PJK ratios with disruption of soft tissue above UIV, especially ligamentum flavum and posterior interspinous ligament, to put proximal anchors for curve correction. Interestingly in this fifty AIS population, they found out that the PJK angle was not statistically correlated to thoracic kyphosis changes, SVA changes, or LL changes.

### 5. Instrumentation relation

After the introduction of thoracic pedicle screw instrumentation, an increasing number of literature query its hypokyphotic effect on already decreased thoracic kyphosis. In concordance with this, cervical sagittal alignment also comes into the attention of authors after the results of flat spine cases published(27). Legaretta et al.(27) showed that although the cervical spine tends to decompensate and acquire a kyphotic sagittal profile regardless of the surgical technique used, the hybrid system is better in terms of cervical kyphosis correction when compared to all pedicle screw construct due to their thoracic kyphosis recreation effect. They also noticed for further surgeries that instrumentation above the T4 level has a cervical kyphotic effect and suggests it should be avoided if it is possible. Similarly, in another study, cervical lordosis after thoracic instrumentation was best accomplished with hybrid instrumentation compared to all pedicle screw constructs(28). The authors also showed a gradual increase in cervical lordosis postoperatively in 2 years.

Another study investigated the hypokyphotic effect of the pedicle screw construct and showed that the low-density strategic pedicle screw construct system is favorable in terms of avoiding hypokyphosis. They also reported favorable sagittal pelvic parameters regarding increased sacral slope and correction of pelvic retroversion(29). To summarize, they showed low-density constructs favorable in avoiding flat back with sufficient coronal plane correction. Charles et al.(30) showed improved cervical lordosis with instrumentation of hybrid construct and in situ bending in 52 idiopathic scoliosis cases. They also subdivided the population into five distinctive cervical alignment profiles; lordotic, hypolordotic, kyphotic, sigmoid with cranial lordosis, sigmoid with caudal lordosis.

In contrast to previous studies, Berger et al.(31) showed improved cervical lordosis after pedicle screw instrumentation in Lenke 1 curves. However, they did not stratify the population into who have Ponte like osteotomies, which is done with the intention to improve thoracic kyphosis.

Simultaneous double rod rotation technique (SDRRT) has improved to restore normal thoracic kyphotic alignment in the AIS population. It is pub-

lished in the literature that SDRRT increased both hypokyphotic and normokyphotic spine into a more harmonious sagittal plane by an increase in lower cervical lordosis and a decrease in compensation of upper cervical lordosis.(32)

### 6. Miscellaneous Topic


Cervical sagittal configuration changes after AIS surgery seem to be related to the instrumentation of the thoracic curve, but this is not always necessary. A recent article from Tauchi et al. (33) showed that cervical alignment correction could be achieved with selective instrumentation of Lenke 5c curves. Also, the sagittal modifier negative group has achieved better results in the correction of normal spinal curvatures. Another study of Yan et al. (34) showed that lumbar AIS patients maintain larger cervical lordosis degrees than thoracic AIS patients at 2-year follow-up. Even though both groups have improved cervical lordosis, this is due to preoperative better cervical lordosis in lumbar AIS patients.

It is not only sagittal plane changes that affect cervical sagittal alignment. Coronal plane deformities also have an impact on cervical sagittal alignment. Tang et al.(35) showed in a descriptive study of AIS and normal population comparison, coronal plane changes such as apical vertebral translation, T1 coronal tilt, and lumbopelvic relationship are different in the cervical kyphosis group compared to the cervical lordosis group. In another study, there is a significant correlation between the high coronal thoracic curve and CK prevalence, not with positive cervical sagittal balance (36) Preoperative greater proximal thoracic curve magnitude and C2-C7 lordosis are the risk factors for aggravation of cervical sagittal alignment (CSA)(37). Although improvement was seen in CSA, %54,4 of patients still have cervical kyphosis after AIS surgery, and SRS-22 scores showed no difference based on the CSA in this study cohort.

### Conclusion

It seems like cervical sagittal balance still will be one of the main topics of spine authors in future studies. Prospective studies will be more convincing since retrospective studies show the opposite results. A meta-analysis of future prospective studies will clarify

the confusion on upper instrumentation level effect on CSB, implant choice of instrumentation, PJK reasons, correlation with global spine balance, and finally, relationship with whole-body alignment. Correction of thoracic hypokyphosis, especially proximal thoracic, could stimulate cervical lordotic

changes over time. Flattening of the entire spine either by surgery or bracing ends up with cervical kyphosis. 

### Conflict of interest

The authors declare no conflicts of interest.

## REFERENCES

1. Ling FP, Chevillotte T, Leglise A, et al. Which parameters are relevant in sagittal balance analysis of the cervical spine? A literature review. *Eur Spine J*. 2018;27(Suppl 1):8-15.
2. Le Huec JC, Thompson W, Mohsinaly Y, et al. Sagittal balance of the spine. *Eur Spine J*. 2019;28(9):1889-1905.
3. Tang JA, Scheer JK, Smith JS, et al. The impact of standing regional cervical sagittal alignment on outcomes in posterior cervical fusion surgery. *Neurosurgery*. 2012;71(3):662-669; discussion 669.
4. Bao H, Varghese J, Lafage R, et al. Principal Radiographic Characteristics for Cervical Spinal Deformity: A Health-related Quality-of-life Analysis. *Spine (Phila Pa 1976)*. 2017;42(18):1375-1382.
5. Fan Y, Wang J, Cai M, et al. The Correlation Between Postoperative Cervical Sagittal Alignment and Spine Sagittal Alignment in Adolescent Idiopathic Scoliosis: A Meta-Analysis. *World Neurosurg*. 2020;134:e311-e316.
6. Abelin-Genevois K, Sassi D, Verdun S, et al. Sagittal classification in adolescent idiopathic scoliosis: original description and therapeutic implications. *Eur Spine J*. 2018;27(9):2192-2202.
7. Smith JS, Shaffrey CI, Lafage V, et al. Spontaneous improvement of cervical alignment after correction of global sagittal balance following pedicle subtraction osteotomy. *J Neurosurg Spine*. 2012;17(4):300-307.
8. Wang L, Liu X. Cervical sagittal alignment in adolescent idiopathic scoliosis patients (Lenke type 1-6). *J Orthop Sci*. 2017;22(2):254-259.
9. Moreira Pinto E, Alves J, de Castro AM, et al. High thoracic kyphosis: impact on total thoracic kyphosis and cervical alignment in patients with adolescent idiopathic scoliosis. *Spine deformity*. 2020;8(4):647-653.
10. Akbar M, Almansour H, Lafage R, et al. Sagittal alignment of the cervical spine in the setting of adolescent idiopathic scoliosis. *J Neurosurg Spine*. 2018;29(5):506-514.
11. Pepke W, Almansour H, Lafage R, et al. Cervical spine alignment following surgery for adolescent idiopathic scoliosis (AIS): a pre-to-post analysis of 81 patients. *BMC Surg*. 2019;19(1):7.
12. Ito K, Imagama S, Ito Z, et al. Analysis of cervical kyphosis and spinal balance in young idiopathic scoliosis patients classified by the apex of thoracic kyphosis. *Eur Spine J*. 2016;25(10):3220-3225.
13. Hilibrand AS. The Sagittal Alignment of the Cervical Spine in Adolescent Idiopathic Scoliosis. In: 1995:627-632.
14. Persson PR, Hirschfeld H, Nilsson-Wikmar L. Associated sagittal spinal movements in performance of head pro- and retraction in healthy women: a kinematic analysis. *Man Ther*. 2007;12(2):119-125.
15. Canavese F, Turcot K, De Rosa V, et al. Cervical spine sagittal alignment variations following posterior spinal fusion and instrumentation for adolescent idiopathic scoliosis. *Eur Spine J*. 2011;20(7):1141-1148.
16. Shimizu T, Cerpa M, Lehman RA, et al. Reciprocal Change in Sagittal Profiles After Adolescent Idiopathic Scoliosis Surgery With Segmental Pedicle Screw Construct: A Full-body X-ray Analysis. *Spine (Phila Pa 1976)*. 2019;44(24):1705-1714.
17. Zhang Z, Ma X, Yin J, et al. Alterations of sagittal alignment and thoracic cage parameters after long-term bracing in adolescents with idiopathic scoliosis. *Orthop Traumatol Surg Res*. 2020.
18. Ketenci IE, Yanik HS, Erdem S. The effect of upper instrumented vertebra level on cervical sagittal alignment in Lenke 1 adolescent idiopathic scoliosis. *Orthop Traumatol Surg Res*. 2018;104(5):623-629.
19. Zhao J, Chen Z, Yang M, et al. Does spinal fusion to T2, T3, or T4 affects sagittal alignment of the cervical spine in Lenke 1 AIS patients: A retrospective study. *Medicine (Baltimore)*. 2018;97(5):e9764.
20. Legarreta CA, Barrios C, Rositto GE, et al. Cervical and thoracic sagittal misalignment after surgery for adoles-

- cent idiopathic scoliosis: a comparative study of all pedicle screws versus hybrid instrumentation. *Spine (Phila Pa 1976)*. 2014;39(16):1330-1337.
21. Yanik HS, Ketenci IE, Erdem S. Cervical Sagittal Alignment in Extensive Fusions for Lenke 3C and 6C Scoliosis: The Effect of Upper Instrumented Vertebra. *Spine (Phila Pa 1976)*. 2017;42(6):E355-e362.
  22. Ramírez-Villaescusa J, Cambronero Honrubia I, Ruiz-Picazo D, et al. Thoracic pedicle subtraction osteotomy for correction of proximal junctional kyphosis after surgery for adolescent idiopathic scoliosis: A case report. *Int J Surg Case Rep*. 2020;67:66-70.
  23. Sun Z, Qiu G, Zhao Y, et al. Risk factors of proximal junctional angle increase after selective posterior thoracolumbar/lumbar fusion in patients with adolescent idiopathic scoliosis. *Eur Spine J*. 2015;24(2):290-297.
  24. Homans JF, Kruyt MC, Schlösser TPC, et al. Changes in the Position of the Junctional Vertebrae After Posterior Spinal Fusion in Adolescent Idiopathic Scoliosis: Implication in Risk Assessment of Proximal Junctional Kyphosis Development. *J Pediatr Orthop*. 2020;40(2):e84-e90.
  25. Ferrero E, Bocahut N, Lefevre Y, et al. Proximal junctional kyphosis in thoracic adolescent idiopathic scoliosis: risk factors and compensatory mechanisms in a multicenter national cohort. *Eur Spine J*. 2018;27(9):2241-2250.
  26. Ghailane S, Pesenti S, Peltier E, et al. Posterior elements disruption with hybrid constructs in AIS patients: is there an impact on proximal junctional kyphosis? *Arch Orthop Trauma Surg*. 2017;137(5):631-635.
  27. Legarreta CA, Barrios C, Rositto GE, et al. Cervical and Thoracic Sagittal Misalignment After Surgery for Adolescent Idiopathic Scoliosis. *Spine (Phila Pa 1976)*. 2014;39(16):1330-1337.
  28. Ilharreborde B, Vidal C, Skalli W, et al. Sagittal alignment of the cervical spine in adolescent idiopathic scoliosis treated by posteromedial translation. *Eur Spine J*. 2013;22(2):330-337.
  29. Dumpa SR, Shetty AP, Aiyer SN, et al. Reciprocal Changes in Sagittal Alignment in Adolescent Idiopathic Scoliosis Patients Following Strategic Pedicle Screw Fixation. *Asian spine journal*. 2018;12(2):300-308.
  30. Charles YP, Sfeir G, Matter-Parrat V, et al. Cervical sagittal alignment in idiopathic scoliosis treated by posterior instrumentation and in situ bending. *Spine (Phila Pa 1976)*. 2015;40(7):E419-427.
  31. Berger RJ, Sultan AA, Tanenbaum JE, et al. Cervical sagittal alignment and the impact of posterior spinal instrumented fusion in patients with Lenke type 1 adolescent idiopathic scoliosis. *Journal of spine surgery (Hong Kong)*. 2018;4(2):342-348.
  32. Miyazaki M, Ishihara T, Abe T, et al. Analysis of reciprocal changes in upper cervical profiles after posterior spinal fusion with the simultaneous double rod rotation technique for adolescent idiopathic scoliosis. *Orthop Traumatol Surg Res*. 2020.
  33. Tauchi R, Kawakami N, Ohara T, et al. Sagittal Alignment Profile Following Selective Thoracolumbar/Lumbar Fusion in Patients With Lenke Type 5C Adolescent Idiopathic Scoliosis. *Spine (Phila Pa 1976)*. 2019;44(17):1193-1200.
  34. Yan P, Zhang Y, Liu S, et al. Sagittal Profile Response of Cervical Spine After Posterior Correction in Thoracic and Lumbar Adolescent Idiopathic Scoliosis: Correlation with Thoracic Kyphosis? *World Neurosurg*. 2018;120:e333-e341.
  35. Tang Y, Xu X, Zhu F, et al. Incidence and Risk Factors of Cervical Kyphosis in Patients with Adolescent Idiopathic Scoliosis. *World Neurosurg*. 2019;127:e788-e792.
  36. Hu X, Lieberman IH. Prevalence and Factors Affecting Cervical Deformity in Adolescent Idiopathic Scoliosis Patients: A Single-Center Retrospective Radiological Study. *International journal of spine surgery*. 2018;12(1):22-25.
  37. Cho JH, Hwang CJ, Choi YH, et al. Cervical sagittal alignment in patients with adolescent idiopathic scoliosis: is it corrected by surgery? *J Neurosurg Pediatr*. 2018;21(3):292-301.