

Ligament reconstruction and tendon interposition arthroplasty for the treatment of 1st Carpo-Meta-Carpal joint arthritis

Panagiotis N. Giannakopoulos¹, Konstantinos Kourkoutas¹, George Kasimatis², Nikolaos Vlachos-Zounelis³

¹*Athens Medical Center, Upper Extremity and Microsurgery Unit, Athens, Greece*

²*Athens Medical Center, Athens, Greece.*

³*Athens Medical Group, Psychiko Clinic, Athens, Greece.*

ABSTRACT

Arthritis of the basal joint of the thumb is the most common form of hand arthritis. Various operations have been described for surgical treatment of this type of arthritis, such as simple excision, excision with ligament reconstruction, use of autogenous or synthetic grafts and total joint arthroplasty. Although many authors believe that simple excision with or without interposition of tendon or synthetic graft is adequate, the technique of ligament reconstruction with tendon interposition (LRTI) offers an additional and important factor to avoid the subsidence of the 1st metacarpal.

Materials and Methods. Between 1995 and 2018, 115 patients with basal joint arthritis of the thumb underwent surgical treatment in our institution. Sixty-five of them underwent operation with a modified technique of Barton and Pellegrini, using a suture anchor for the attachment of half of the flexor carpi radialis tendon. This technique simplifies the operation, making it feasible for a wider range of hand surgeons. Additionally, the patients underwent tenotomy of accessory bands of abductor pollicis longus when present.

Results. Assessment of the results was based on pain reduction, grip and pinch strength, as well as on the improvement of thumb motion. Reduction of 1st metacarpal height and the deformity of the thumb were also evaluated. Complications were minor following this procedure.

Conclusions. Excision arthroplasty and ligament reconstruction with tendon interposition (LRTI) remains a gold standard for treatment of basal joint arthritis of the thumb. The modification of the technique with the use of a suture anchor instead of an intraosseous tendon graft, offers a significant simplification and should be considered as an attractive alternative. Tenotomy of the accessory bands of abductor pollicis longus may further improve the final clinical outcome.

KEY WORDS: Thumb, Arthritis, Ligament, Tendon, Reconstruction

CORRESPONDING
AUTHOR,
GUARANTOR

Panagiotis N. Giannakopoulos MD, Consultant Orthopaedic Surgeon, Upper Extremity and Microsurgery Unit, Athens Medical Center, 5-7 Distomou Str, 11525, Athens, Greece. Phone: 00302106105387 E-mail address: pgiannak@otenet.gr

Thumb carpometacarpal (CMC) arthritis, often referred to as “Rhizarthrosis”, is a very common pathology, especially in elderly women. The incidence is high, approximately 15% in the general population. The pathology is present in 25% of men and 40% of women over 75 years old. Lately, the use of mobile phones, especially typing for SMS, has increased the incidence of this degenerative disorder. Gervis in 1949, first described simple trapeziectomy for the treatment of the condition and pain relief (1). Since then, a lot of variations in the surgical technique have been described, in order to provide pain relief and improvement of the pinch strength the thumb.

CMC joint anatomy

Thumb CMC joint is a biconcave saddle joint and consists of the articulation between the base of the first metacarpal and the distal end of trapezium. Trapezium-trapezoid, scaphotrapezial and trapezium-index metacarpal articulations are functionally related to the CMC joint. The curved articular surfaces of the CMC joint allow for limited stability only, which is provided by the ligaments. These ligaments play an important role in the static stability and dynamic control of the joint. Although studies have described three to sixteen ligaments, only a few have been directly implicated in joint stability [1]. Controversy exists regarding the main thumb CMC joint stabilizer. Ladd L.A et al, in their study comprising thirty cadaveric hands, identified seven principal ligaments. Three capsular ligaments (the dorsal radial, dorsal central and posterior oblique ligament) referred to as “dorsal deltoid ligament complex”, are located on the dorsum of the CMC joint and are found consistently stout, two volar ligaments (anterior oblique and ulnar collateral ligament), and two ulnar ligaments (the first dorsal trapeziometacarpal and the intercarpal ligament). Their morphometric findings on the dorsal radial ligament revealed it is of primary importance concerning stability, disproving the principal importance of the anterior oblique ligament that corresponds more to a hypocellular and disorganized structure rather than a true ligament [2][3]. Moreover, taking into account that highly innervated ligaments are believed to have a significant role in joint stability, as well as in the neuromuscular and proprioceptive function of the joint

[4], the greater innervation of the dorsal ligaments compared with the volar ones, furthermore supports the importance of the dorsal ligaments as stabilizers of the thumb CMC joint [2,3].

The presence of Accessory Abductor Pollicis Longus Tendons (AAPLT) may also play a role in CMC joint stability and arthritis. Zancolli EA (5) and Brunelli (6) reported that the presence of an accessory abductor pollicis brevis tendon may result in CMC instability and arthritis. On the other hand, Bouchlis G (7) in 1997, Roh MS in 2000 (8) and Schlz CU IN 2002 (9), in their anatomic studies found no significant relationship between osteoarthritis of the basal joint of the thumb and the supernumerary slips of the abductor pollicis longus tendon.

Evaluation and treatment

In the first stages of arthritis, the most common symptom is pain at the base of the thumb during daily activities. At late stages, there is pain at rest, difficulty in pinching and grasping and the characteristic “Z” deformity. Standard radiographs (AP and lateral views), show joint space narrowing, presence of osteophytes and the hyperextension of the MCP joint. Differential diagnosis must be done from De Quervain’s syndrome, STT arthritis and scaphoid nonunion, with or without arthritis.

Eaton in 1969, suggested a staging system for the arthritis of the basal joint of the thumb. In stage I, we have normal joint at x-rays and we have only synovitis. In stage II, joint space narrowing appears, with osteophytes <2 mm. Stage III is characterized by joint space narrowing and osteophytes >2 mm. Finally, in stage IV scapho-trapezium joint space involvement is presented (10).

Conservative treatment in early stages is effective, and it includes non-steroid anti-inflammatory medication and application of a thumb spica cast. Injections, such as steroids or hyaluronic acid, are the second line of treatment.

Surgery for CMC arthritis is recommended when non-operative measures fail to control the pain and functional limitations imposed by the disease. Constant pain, deformity, loss of motion and loss of grip and pinch strength are the most common symptoms. Additionally, surgery is also suggested in cases where

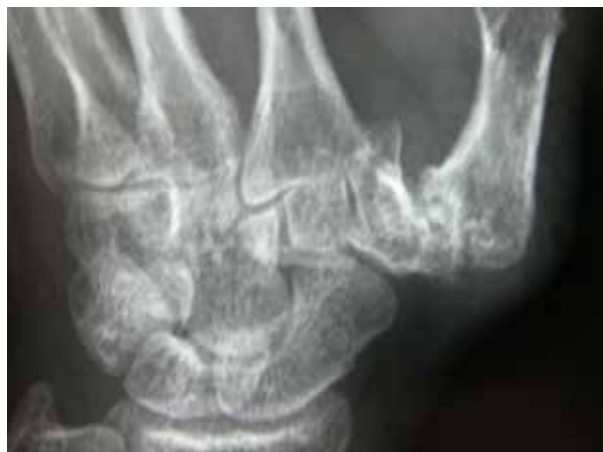
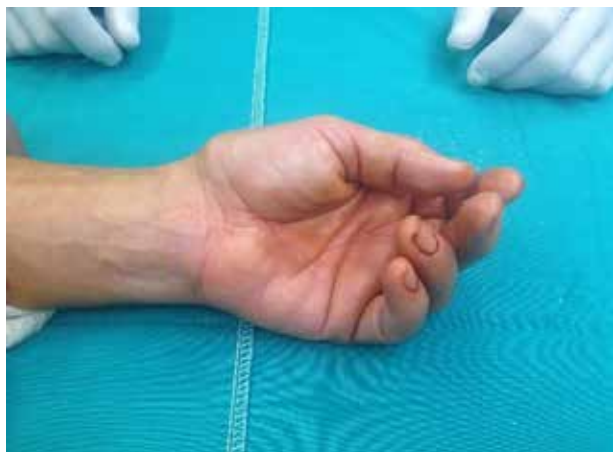
Fig 1, 2. Typical appearance of CMC arthritis

there is a failure from a previous arthroplasty (pain, dislocation), as well as in some relative indications (younger patient who requires grip and pinch strength in his/her work activity). There are a lot of surgical techniques for the treatment of CMC arthritis. The choice of the appropriate procedure for each patient is a challenging decision and it requires a lot of experience. In early stages of arthritis and with satisfactory articular surfaces, we could proceed to an AAPLT tenotomy or to ligament reconstruction with tendon graft, especially when instability and subluxation are present. Other options are arthroscopic debridement of the joint or a 1st metacarpal closing wedge osteotomy in dorsal extension (5).

For Eaton stage II - IV thumb CMC arthritis, the available procedures are listed below: simple trapezium excision called as “hematoma distraction arthroplasty”, trapezium excision with ligament reconstruction and tendon interposition (LRTI arthroplasty), suture suspensoplasty, graft jacket / dura mater usage, total joint replacement, CMC denervation and fusion.

Haematoma distraction arthroplasty

Hematoma distraction arthroplasty is performed under general or regional anesthesia and using a tourniquet. A longitudinal or slight curved incision on the radial aspect of the wrist, along the radio-dorsal aspect of the thumb metacarpal and the axis of the APL and EPB, is carried out. Local branches of the radial sensory nerve and radial artery should be identified and protected during this approach. The incision is then

deepened in the interval between APL and EPB and the joint capsule is exposed on its radio-dorsal aspect. It is important to notice that we have to recognize the trapezium and to be sure that we will remove it alone because sometimes it is too difficult to separate it from the trapezoid or the base of the metacarpal. An osteotomy of the trapezium with an osteotome and a subsequent resection with a rongeur is performed. Additionally, FCR tendon must be identified in the deep layer and it should be carefully preserved. Complete removal of the trapezium should be attempted to avoid leaving behind any small bone fragments that may later cause pain with joint movements. The most important step is pinning of the thumb metacarpal in the proper position. With the thumb in wide palmar abduction, slight opposition, and distraction until firm resistance is encountered, a single 1.6-mm K-wire is passed from the thumb metacarpal base until it engages securely in either the base of the index metacarpal or in the trapezoid. Abduction and pronation of the thumb with the fingers and the thumb passively formed into a fist, the thumb tip should be pointed between the middle and ring fingers just distal to the proximal interphalangeal joints. In general, the space that will be eventually filled by the hematoma fluid, should allow just the insertion of the index fingertip of the surgeon. Postoperatively, a thumb spica cast is applied for 5-6 weeks and after this period we can remove the K-wire in order to start physiotherapy to restore the full range of motion and to strengthen the flexion - extension and abduction - adduction movements of the thumb (11).

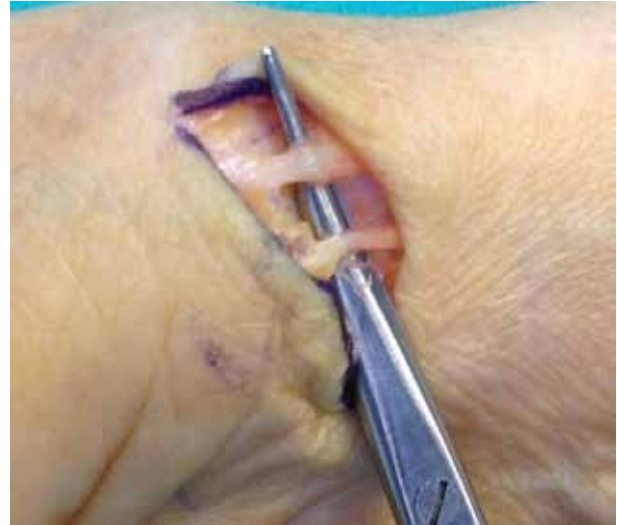
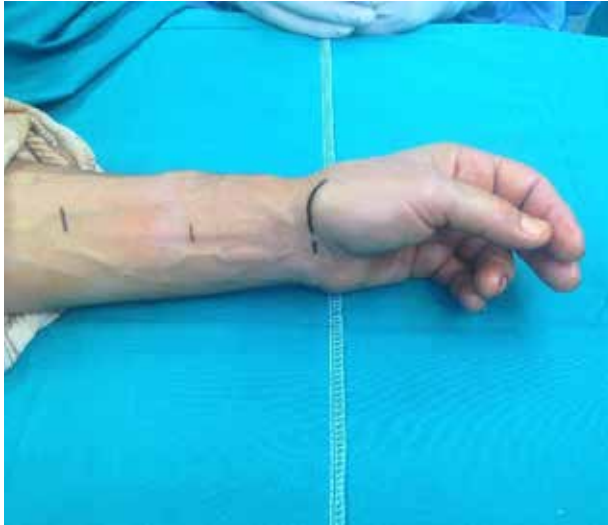
Fig. 3, 4. Palmar incisions and the identification of the radial nerve branches.

Ligament reconstruction and tendon interposition (LRTI) arthroplasty

Surgical management of basal joint arthritis of the thumb referred to as “Ligament Reconstruction with Tendon Interposition arthroplasty- LRTI”, was first suggested by Burton RI and Pellegrini VD in 1988 (12). They used a part of the FCR to stabilize the 1st metacarpal and to reconstruct the palmar oblique ligament. They reported excellent results in 92% of the cases. Weilby in 1988 reported that simple excision of the trapezium resulted in an unstable joint with telescoping motion, pain, weakness and a tendency to adduction deformity in 30% of the patients (13). He also suggested the stabilization of the 1st metacarpal using FCR and APL tendons. To achieve the reconstruction of the ligament and the stabilization of 1st metacarpal, different methods have been reported in the literature. Palmaris longus, Extensor Carpi Radialis Longus, as well as a combination of FCR and APL tendons are among others. But we have to notice that after careful study of these modifications, they do not present better outcomes than the initial procedure, which is based on the use of half of FCR tendon (14,15,16,17). Taylor N. in 2005, also reported a modification of the LRTI technique, replacing the bone tunnel with the use of a bone anchor for the entire FCR fixation (18).

Arthrodesis

Arthrodesis is performed through either a volar or

dorsal approach to the trapezio-metacarpal joint. With the joint distracted using traction on the thumb, the articular cartilage and the subchondral bone on the opposing surfaces of the trapezium and the base of the thumb metacarpal are removed. The remaining surfaces are then fused, supplemented with autologous bone graft harvested from the distal radius. The position for arthrodesis is such that the distal phalanx of the thumb is resting on the middle phalanx of the index finger of a fully clenched fist. Fixation is performed with multiple K-wires pins, tension band fixation, or a plate. Postoperative immobilization consists of a forearm-based thumb spica splint that is kept for six weeks. If K-wires pins are used, they are removed at six weeks, regardless of the radiological evaluation (19).

Allograft use

An alternative option to face up CMC arthritis in patients with Eaton stages III, and IV is the use of an allograft (Graftjacket or fascia lata), as the material for arthroplasty, in order to avoid the morbidity that has been associated with the harvest of the flexor carpi radialis tendon. Graftjacket is an acellular dermal matrix allograft which can be used instead of the FCR graft. Trapezium excision and identification of FCR are performed first. The allograft is then cut in order to create a 15-cm strip. The strip should be passed around the FCR and sutured at the base of 1st metacarpal through

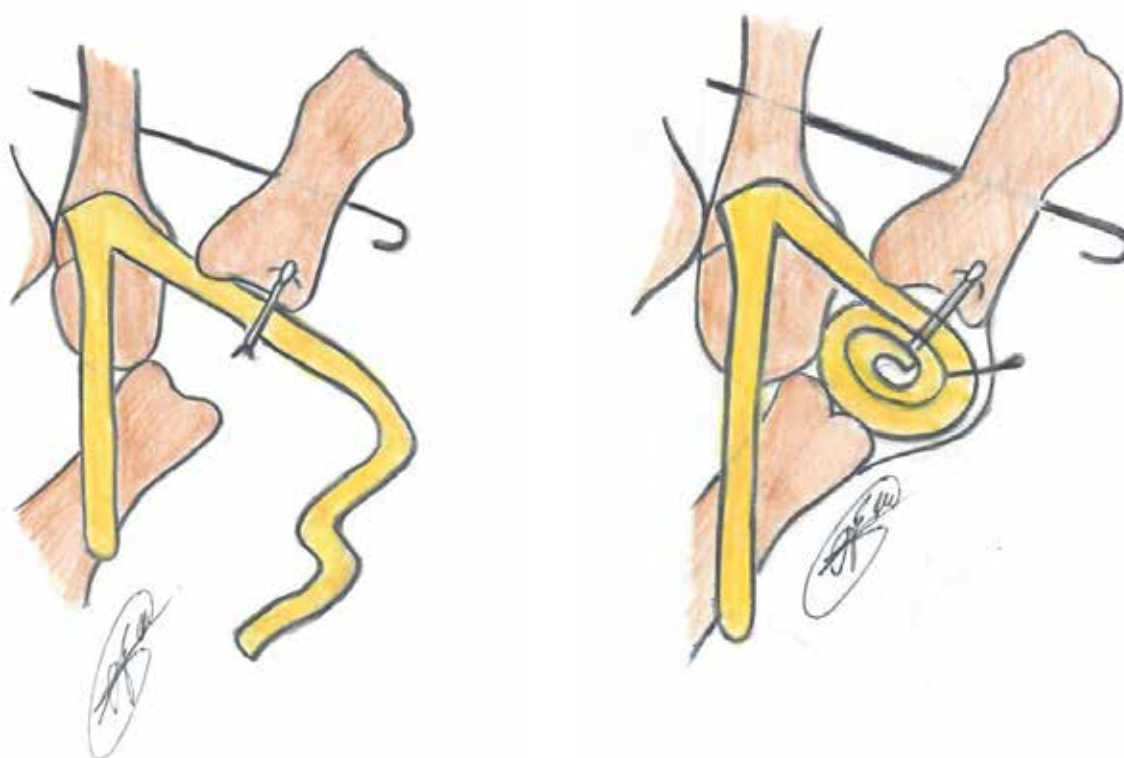


Fig. 5. Schematic representation of the surgical technique; depicts half of FCR fixation at the base of 1st metacarpal with a bone anchor.

a bony drill hole. The remaining portion of the allograft is fashioned as an interposition mass (anchovy) and is interposed between the scaphoid and the base of the first metacarpal. Postoperatively, same protocol as for the LRTI technique should be followed. The fascia lata allograft is also used as a “pillow” for interposition in the place of the excised trapezium, without ligament reconstruction (20,21).

Implant arthroplasty

In this method, all or part of the damaged thumb joint is removed and replaced it with an artificial implant. Silicone was the material which was used to design the first prostheses. In the more recent years, metal or pyrocarbon prostheses and cushioning synthetic spacers have prevailed in hand surgery. Older patients with lower demands may benefit from metal joint arthroplasties. On the contrary, young and active patients may have better outcome with the use of spacers. However, it must be noticed that although there

are some advantages from the use of implants, the rate of complications and the failure of implants (osteolysis, fracture, inflammation, persistent pain) is high. Till now, implant arthroplasty for CMC arthritis is not such a reliable method as the traditional procedures (22,23,24,25).

CMC denervation

The innervation of the first CMC joint is believed to arise from branches of the four principle nerves that surround it: the superficial branch of the radial nerve, palmar cutaneous branch of the median nerve, recurrent branch of the median nerve, and the lateral antebrachial cutaneous nerve. In selected patients, partial, volar first CMC joint denervation is possible with long term relief of pain and increased hand function (26).

Author's preferred method

LRTI arthroplasty remains one of the most popular procedures for the treatment of CMC arthritis. The

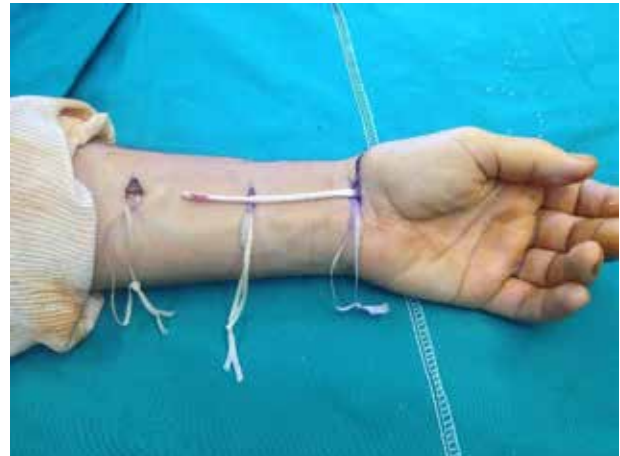
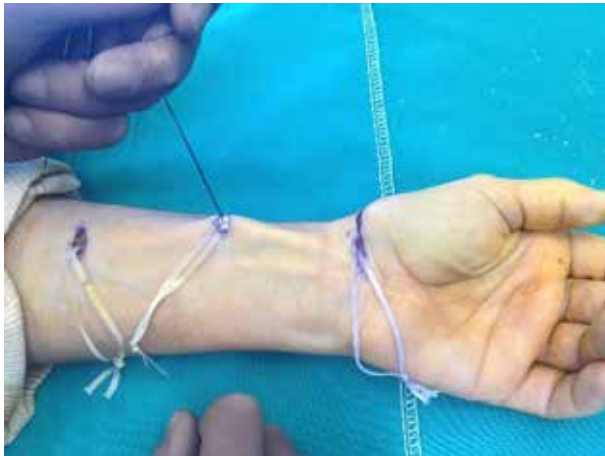


Fig. 6, 7. One half of FCR tendon harvesting.

goal of treatment is to excise the arthritic joint surfaces and to restore thumb metacarpal stability, along with reconstruction of the palmar ligament. In addition, tendon interposition reduces bony impingement. In our practice, we prefer a modified LRTI technique, harvesting half of the FCR tendon and fixing it at the base of the first metacarpal with a bone anchor. In patients with rheumatoid arthritis or other systematic disease, simple excision of trapezium is adequate.

Surgical note

The procedure can be performed under regional anesthesia. We prefer the palmar approach, as it is safer for the sensory branch of the radial nerve. Additional advantages are the protection of the dorsal ligaments and the better visualization of the FCR tendon. Moreover, it produces a more cosmetic scar. The dorsal approach, introduced by Burdon / Pellegrini has a higher risk for superficial radial nerve injury and it causes a less cosmetic scar. The superficial branches of the radial nerve must therefore be identified and protected.

We then proceed to AAPLT tenotomy, when accessory slips exist. Although there is no evidence based reports on the necessity for this tenotomy, we believe that the AAPLT is a possible contributing factor for the appearance of the 1st metacarpal collapse. Excision of the trapezium is the next step. Trapezium removal is not a simple stage of the procedure and removing the entire bone is not always effective. I prefer to create a big hole in the center of trapezium with a 4.5mm drill, which facilitates the easier and complete bone removal

in pieces with the use of a rongeur (Luer). C-arm fluoroscopy confirmation is useful. We must be very careful in order to remove all the bony fragments, because the presence of extensive osteophytes may sometimes cause difficulty in recognizing the articular surfaces, especially between the trapezoid and the trapezium. In addition, special care should be taken not to damage the FCR during trapezium excision. Extensive bone removal due to significant osteophytes (degenerative bone fusion) cannot usually lead to poor or fair results. The one-half of FCR tendon harvesting (radial aspect) must be performed. The half of the FCR tendon is harvested easier with the use of a strong suture placed within the tendon and separating it in the middle, through several stab incisions on the forearm. The tendon must be divided up to its insertion on the base of second metacarpal. The use of one-half of the FCR tendon prevents ulnar deviation of the hand. On the other hand, it may also provide a second option for ligament reconstruction in revision cases. However, in 2000, Varitimidis S. and Sotereanos D. (27) reported that the entire FCR could also be used, without significant hand morbidity. Reduction of the 1st metacarpal is very important and C-arm confirmation should be always performed. We perform the stabilization between the 1st and 2nd metacarpal as a standard procedure, using a 1.4 mm k-wire in 45° of abduction, flexion and rotation of the thumb. Ligament reconstruction of the 1st metacarpal is also important. The original technique requires creation of a tunnel for FCR fixation, which has some difficulties in its implementation. We

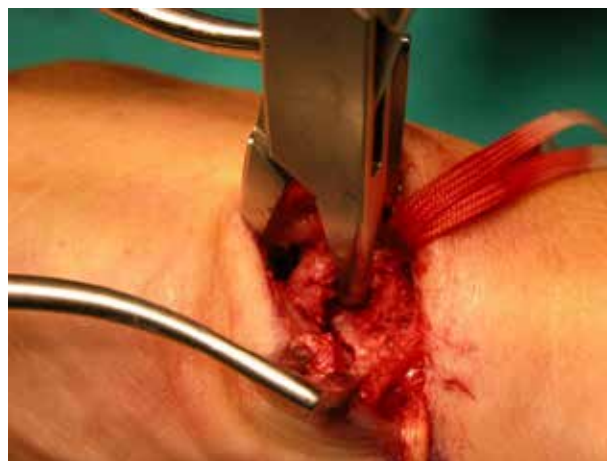
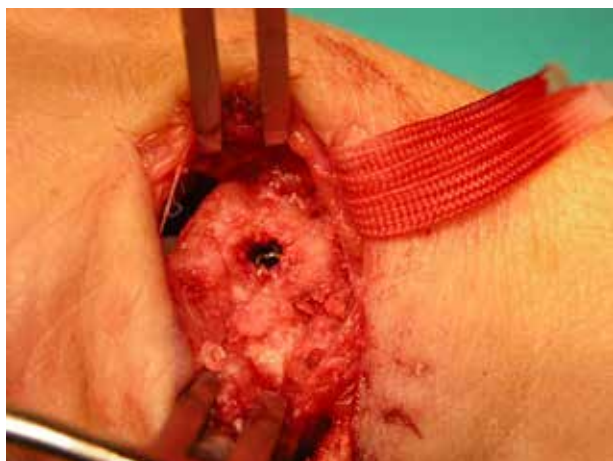
Fig. 8, 9. Trapezium removal after a big hole is drilled in the center of trapezium.

modified this technique by using a bone anchor, which simplifies the procedure and in addition, it reduces the surgical trauma to the capsule and the ligaments. The anchor placement should be in the radial and palmar surface of the base of 1st metacarpal, in order to substitute the palmar ligaments. The adequate tension of the graft is crucial and we must avoid over tension. The remaining tendon is sutured with the capsule and the rest is placed as interposition mass in the trapezoid space. Finally, capsule repair should be performed. Blood drainage is used in every case.

De Quervain's disease, trigger finger and carpal tunnel syndrome are often associated with CMC arthritis and additional release may be necessary.

Postoperative management includes thumb spica cast for 6 weeks. After this period, the k-wire should be removed. Normally, the patient follows a self-rehabilitation program and physiotherapy is not necessary. Full activity is permitted after a period of 3 months.

The complications of the procedure are limited. The most common one is a proximal migration of the thumb, which leads to loss of strength (less than "hematoma arthroplasty") and to "Z" deformity (swan neck). Injury of the superficial branch of the radial nerve is less common with palmar incision. Others complications are FCR tendonitis, De Quervain's Syndrome and CRPS. Rare complications may be due to pin placement, pin track infection, pin migration or breakage, and 1st or 2nd metacarpal fracture. Excessive bone removal, as a part of trapezoid, may also be noted.

Materials and results

Between 1995 and 2018 more than 115 patients with Eaton stage II-IV arthritis of basal joint of the thumb were treated surgically by the senior author (P.N.G.). There were two groups. First group of 40 patients was operated between 1995 and 2004 using the technique which was described by Burton and Pellegrini. Between 2005 and 2018, a second group of 65 patients was operated with the modified technique using a bone anchor. Proportion of women and men was 8:2 and the average age was 65 years (range 55-76).

At the follow-up examination, the patients were evaluated for pain relief, grip strength, lateral and pulp pinch, as well as thumb motion. Migration of the 1st metacarpal was also measured. Pain relief was 94-96%, grip strength increased 87- 90% and the lateral pinch increased 77-80%. Height loss was 15-25 %. The tip of the thumb was able to touch the little finger in a percentage of 95-97% of patients. Mild "Z" deformity was noted in 6-8 % of the patients. The rate of complication was up to 5%, but the majority were minor and did not influence the final outcome. All patients returned back to their previous occupation and they would undergo the surgical procedure again, had they known the result in advance (data not published).

Discussion

Carpometacarpal joint arthritis of the thumb is a quite common condition, especially among women. The thumb has a multi-axial motion leading to premature degeneration. Although hereditary predis-

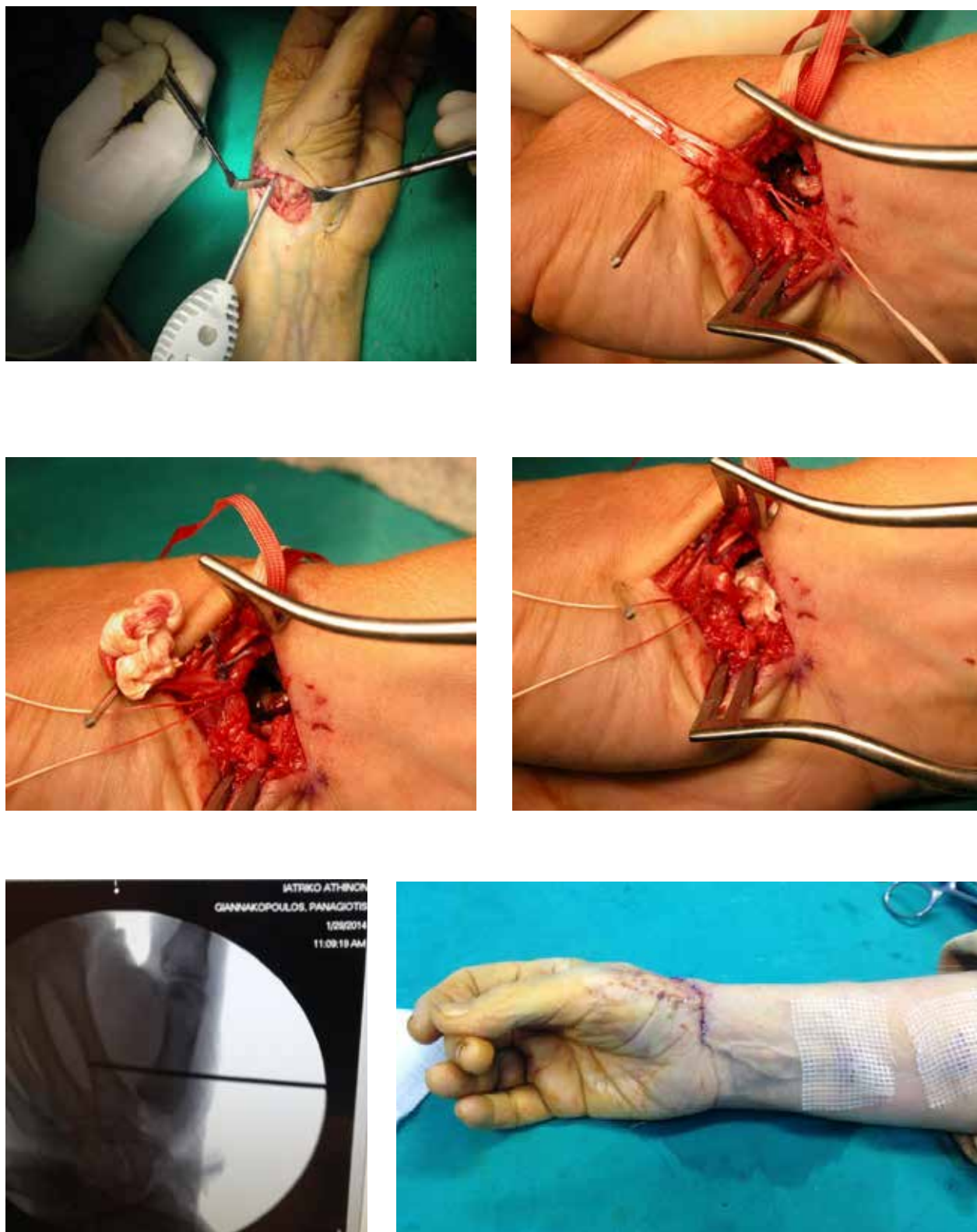


Fig. 10, 11, 12, 13, 14, 15. Following the placement of the bone anchor, the FCR tendon is fixed on the base of 1st metacarpal. The remaining tendon is sutured with the capsule and the rest is placed as an interposition mass in the trapezium space. C-Arm confirmation of the stabilization between the 1st and 2nd metacarpal follows and the wound is finally closed.

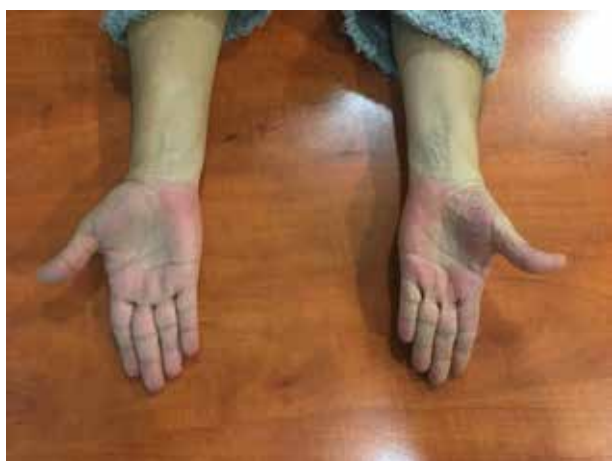
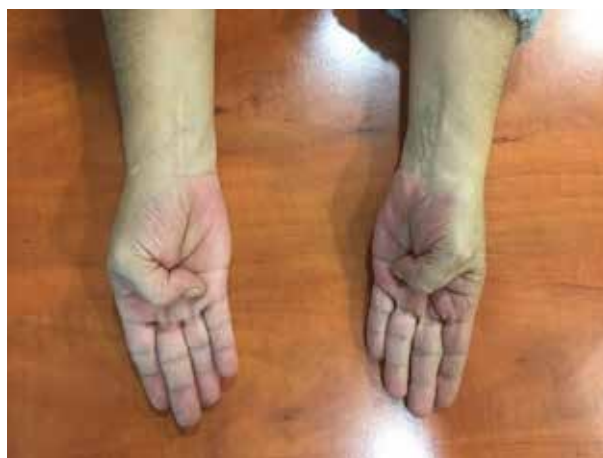
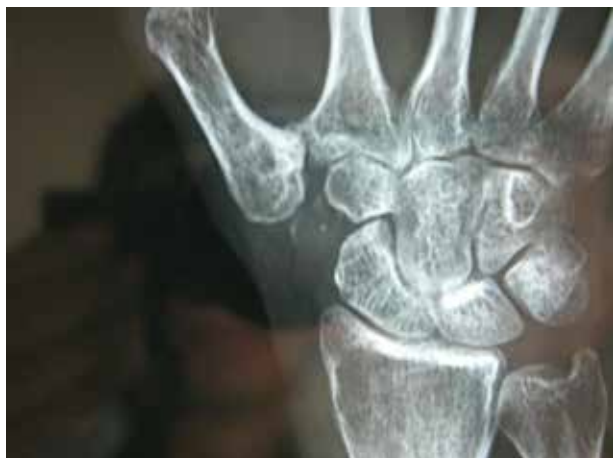Fig. 16, 17, 18. Three years' follow-up. No evidence of 1st metacarpal collapse is noted. The range of motion of the thumb is excellent.

position has not been established, the presence of the AAPLT may be of predictive value. The treatment is usually conservative and successful. Most of the times, it results to a painless type of “arthrodesis” with a degree of deformity of the thumb. Gradual “Z” shape deformity appears and, although it may decrease the functional ability of the hand, it is acceptable most of the times, especially among elderly patients.

The definitive treatment of CMC arthritis is surgical, as it happens in all other joint arthritis. The large variety of different surgical techniques underlines the complexity of its treatment. Simple trapezium excision also referred to as hematoma arthroplasty, is a popular and quite easy technique, with low degree of difficulty concerning rehabilitation (28). Nevertheless, this method usually leads to subsidence of the first metacarpal with the characteristic deformity, which dissatisfies especially the young and elegant women. The relative decrease

of the strength of the thumb, although it is most of the times acceptable, is an additional disadvantage of this particular method. We should also not neglect to report that some studies show no significant difference between the two methods, while others report a higher percentage of complications with the use of tendon for stabilization of the thumb. Total joint arthroplasty is more popular in countries where the designers of the prosthesis perform these replacements. When then are placed properly they result in a good functional outcome, but as with all implants, they have a restricted lifespan. In addition, more serious complications such as infection and periprosthetic fracture have been reported in the literature. The cost of the implants is also high, which is probable the reason why CMC arthroplasty has not globally prevailed over the other methods. The use of interposition materials like Graft jacket has also a high cost, while the results are not superior compared with the initial method of LRTI. Givisis P,

in 2016, published another method called “pillow” technique using a fascia lata allograft, which according to the author has very good results, however it is not widely recognized. Arthrodesis on the other hand can offer powerful hand grip with its known limitations.

LRTI remains for many surgeons the treatment of choice in such extent that it can be characterized as “traditional”. It provides a painless joint, while restoring the stability of the thumb on its anatomic position. Interposition arthroplasty has one more advantage concerning the subsidence of first metacarpal. The final result resembles more to the normal anatomy of the hand and it leads to a better cosmetic and functional outcome. Recent studies noted the importance of dorsal CMC ligaments on the stability of the thumb. Consequently, the preservation of these dorsal ligaments, which is achieved through the palmar approach to the CMC joint, allows for the good outcome. LRTI is a technique which was firstly described by Burton and Pellegrini on 1986. Weilby in 1986 described a modification of the method, while more modifications have been described by other authors. These techniques are effective but difficult for those with inadequate hand surgery training. The description of a simpler surgical technique, which can be performed by the majority of surgeons, while providing the same or even a better surgical outcome, can eventually promote hand surgery. According to this idea, the use of a single bone anchor which replaces the demanding procedure of bone tunnels for the stabilization of the thumb, greatly simplifies the procedure. There are a few studies comparing LRTI arthroplasty with and without bone tunnel which report similar long term result (Vermeulen GM, 2014) (29). In our experience however, a non-tunnel technique can provide a much better outcome with a lower rate of long term complications. Generally, the results of LRTI procedure are very satisfactory. In 1993, Nylen S reported that out of 100 patients treated with LRTI, the pain remained in only at 5 cases, 88 patients were satisfied with the procedure and there was a significant increase in pinch strength and in the ability to perform daily activities (30). In 1996, Lins RE reported an 89% satisfaction rate with pain relief, while 87%


of the patients would undergo this surgical procedure again. Loss of the trapezial space ratio did not decrease the final outcome. In 2000, Varitimidis SE referred that 95% of his patients reported excellent pain relief. A lot of other reports show similar results. Our experience may indicate slightly better results with the modified Burton’s and Pellegrini’s technique with the use of one anchor. On the other hand, comparing the LRTI technique with the simple excision, Naram et al, referred greater incidence of post-operative complications with LRTI group, but he did not compare the final outcome (31).

There are some critical points of the procedure that we should keep in mind. The procedure becomes simpler using a bone anchor, which also decreases the injury of the capsule and the ligaments. Although a slight loss of height of the 1st metacarpal does not indicate a poor outcome, a more serious collapse may result in deformity and functional limitations. The AAPLT tenotomy is not recommended by the literature, but in our opinion, the tenotomy can be useful. Our hypothesis is that as the accessory tendon is found in a large number of patients with basal arthritis of the thumb, and it may be the reason for palmar subluxation of the 1st metacarpal; especially the tendon branch to the thenar eminence, may be related to instability and arthritis. The tenotomy can reduce these forces and decrease the possibility of 1st metacarpal collapse without functional limitations. In our study presented in the annual meeting of HSSH in 2016, all our 16 patients with painful instability and/or primary arthritis of the basal joint of the thumb, were found to have an improvement of their symptoms after an AAPL tenotomy. These results are in agreement with the Zancolli study. In the end, tenotomy cannot have any negative impact. Another point of discussion is the appropriate duration and the method of thumb immobilization. Tendon to bone healing requires immobilization for a period of six weeks. All techniques with ligament reconstruction using tendon grafts (LRTI, Weilby) must follow this protocol. K-wire fixation of the 1st and 2nd metacarpals combined with a spica is a safer practice. Immobilization just with the thumb spica cast is not enough.

Conclusions

A great number of options have been described for the treatment of CMC arthritis. Trapezium excision and ligament reconstruction (LRTI) probably remains the most common and favorable technique. LRTI arthroplasty technique is safe, it provides adequate stability of the thumb, and it offers functional strength and motion. FCR fixation with a bone anchor as a minimal invasive

technique seems simple. Lower rate of risks and complications and slightly better results are noticed. However, there are also alternative options with excellent results and successful outcomes.

On the other hand, there are still some considerations. Is simple excision better than ligament reconstruction? Is an implant or an allograft better than autograft? Should we care about the cost? 

REFERENCES

1. Gervis WH: Excision of the trapezium for osteoarthritis of the trapezio-metacarpal joint J.B.J.S Br 31:537,1949Damen A, van der Lei B, Robinson PH. Carpometacarpal arthritis of the thumb. J. Hand Surg 1996; 21A: 807-812
2. Cardoso FN, Kim HJ, Albertotti F, Botte MJ, Resnick D, Chung CB. .Imaging the Ligaments of the Trapeziometacarpal Joint: MRI Compared with MR Arthrography in Cadaveric specimens. AJR. 2009; 192: W13-19
3. Ladd A, Lee J, Hagert E. Macroscopic and Microscopic Analysis of the Thumb Carpometacarpal Ligaments. J Bone Joint Surg Am. 2012; 94:1468-77
4. Ladd AL, Weiss AP, Crisco JJ, Hagert E, Wolf JM, Glickel SZ, Yao J. The Thumb Carpometacarpal Joint; Anatomy, Hormones, and Biomechanics. Instr Course Lect. 2013; 62: 165-179
5. Zancolli EA. The trapeziometacarpal joint. Tenotomy of the accessory tendons in early osteoarthritis. Hand Clinics 2001; 17(1): 13-43
6. Brunelli GA, Brunelli GR. Anatomical study of distal insertion of the abductor pollicis longus. Concept of a new musculo-tendinous unit: the abductor carpi muscle. Ann Chir Main Memb Super 1991; 10 (6): 569-576
7. Bouchlis GL, Bhatia AZ, Asfazadourian H, Touam C, Vacher C, Oberlin C. Distal insertions of abductor pollicis longus muscle and arthritis of the first carpometacarpal joint in 104 dissections. Ann Chir Main (Ann Hand Surg) 1997; 16 (4): 326-338
8. Roh MS, Strauch RJ, Xu L, Rosenwasser MP, Pawluk RJ, Mow VC, Thenar insertion of abductor pollicis longus accessory tendons and thumb carpometacarpal osteoarthritis. J Hand Surg (Am) 2000; 25(3): 458-63.
9. Schulz CU, Anetzberger H, Pfahler M, Maier M, Reifor HJ. The relation between primary osteoarthritis of the trapeziometacarpal joint and supernumerary slips of the abductor pollicis longus tendon. J Hand Surg (Eu) 2002; 27B (3): 238-241
10. Eaton RG, Littler JW. A study of the base joint of thumb; treatment of its disabilities by fusion. JBJS 1969; 51A (4): 661-668
11. Gray KV and Meals RA. Hematoma and Distraction Arthroplasty for Thumb Basal Joint Osteoarthritis: Minimum 6.5-Year Follow-Up Evaluation. J Hand Surg 2007; 32A: 23-29
12. Burton R, Pellegrini VD. Surgical management of basal joint arthritis of the thumb. Part II. Ligament reconstruction with tendon interposition arthroplasty. J Hand Surg 1986; 11A: 324-332
13. Weilby A. Tendon interposition arthroplasty of the first carpo-metacarpal joint. J Hand Surg 1988; 13 (B), 4: 421-425
14. Davis TR, Brady O, Dias JJ. Excision of the trapezium for osteoarthritis of the trapeziometacarpal joint: a study of the benefit of ligament reconstruction or tendon interposition. J Hand Surg (Am) 2004; 29 (6):1069-1077
15. Lins RE, Gelberman RH, McKeown L, Katz JN, Kadiyala RK. Basal joint arthritis: trapeziectomy with ligament reconstruction and tendon interpo-

REFERENCES

- sition arthroplasty. *J Hand Surg (Am)* 1996; 21 (2): 202-209
16. Tomaino MM. Ligament reconstruction tendon interposition arthroplasty for basal joint arthritis. Rationale, current technique and clinical outcome. *Hand Clin.* 2001; 17 (2): 207-221
 17. Damen A, van der Lei B, Robinson PH. Carpometacarpal arthritis of the thumb. *J Hand Surg* 1996; 21A: 807-812
 18. Taylor N, Strauch R. Suture Anchor Arthroplasty for Thumb Carpometacarpal Osteoarthritis. *J Hand Surg* 2005; 5 (3): 153-158
 19. Hartigan BJ, Stern PJ, Kiefhaber TR. Thumb carpometacarpal osteoarthritis: arthrodesis compared with ligament reconstruction and tendon interposition. *JBJS* 2001; 83 (10): 1470-1478
 20. Kokkalis ZT, Zanaros G, Sotereanos DG. Ligament reconstruction with tendon interposition using an acellular dermal allograft for thumb carpometacarpal arthritis. *Tech Hand up Extrem Surg* 2009; 13 (1): 41-46
 21. Givvisis P, Sachinis NP, Akritopoulos P, Stavridis SI, Chrodoulou A. The "Pillow" technique for thumb carpometacarpal joint arthritis: Cohort study with 10 to 15 years follow-up. *J Hand Surg* 2016
 22. Minami A, Iwasaki N, Kutsumi K, Suenaga N, Yasuda K. A long-term follow-up of silicone-rubber interposition arthroplasty for osteoarthritis of the thumb carpometacarpal joint. *Hand Surg.* 2005; 10(1):77-82
 23. De Smet L, Vandenbergh L, Degreef I. Long-term outcome of trapeziectomy with ligament reconstruction and tendon interposition (LRTI) versus prosthesis arthroplasty for basal joint osteoarthritis of the thumb. *Acta Ortho Belg* 2013; 79 (2): 146-149
 24. Schmidt I. Treatment Options for Thumb Carpometacarpal Joint Osteoarthritis with an Update to the ArpeTM Prosthesis. *Recent Adv Arthroplast* 2018; 2(2): 55 – 63
 25. MacDermid JC, Roth JH, Gregory I, Bain GI. Trapezial arthroplasty with silicone rubber implantation for advanced osteoarthritis of the trapeziometacarpal joint of the thumb. *Can J Surg* 2003; 46 (2): 103-110
 26. Dellon AL. Volar denervation and osteophyte resection to relieve volar CMC joint pain. *Case Reports in Plastic Surgery and Hand Surgery* 2017; 4 (1): 13-16
 27. Varitimidis SE, Fox RJ, King JA, Taras J, Sotereanos DG. Trapeziometacarpal arthroplasty using the entire flexor carpi radialis tendon. *Clin Orthop Relat Res.* 2000; 370: 164-170
 28. Li YK, White TA, Thoma A. Comparison of trapeziectomy and trapeziectomy with ligament reconstruction and tendon interposition: a systemic literature review. *Plast Reconstr Surg* 2011; 128(1): 199-207
 29. Davis TR, Brady O, Dias JJ. Excision of the trapezium for osteoarthritis of the trapeziometacarpal joint: a study of the benefit of ligament reconstruction or tendon interposition. *J Hand Surg (Am)* 2004; 29(6): 1069-1077
 30. Vermeulen GM, Spekreijse KR, Slijper H, Feitz R, Hovius SER, Selles W. Comparison of arthroplasties with or without bone tunnel creation for thumb basal joint arthritis: a randomized controlled trial. *J Hand Surg* 2014; 39 (9): 1692-1698
 31. Nylen S, Johnson A, Rosenquist AM. Trapeziectomy and ligament reconstruction for osteoarthritis of the base of the thumb. A prospective study of 100 operations. *J Hand Surg (Br)* 1993; 18 (5): 616-619
 32. Naram A, Lyons K, Rothkopf DM, Calkins ER, Breen T, Jones M, Shufflebarger JV. Increased complications in trapeziectomy with ligament reconstruction and tendon interposition compared with trapeziectomy alone. *Hand* 2016; 11 (1): 78-82

READY - MADE
CITATION

Giannakopoulos PN, Kourkoutas K, Kasimatis G, Vlachos-Zounelis N. Ligament reconstruction and tendon interposition arthroplasty for the treatment of 1st Carpo-Meta-Carpal joint arthritis. *Acta Orthop Trauma Hell* 2020; 71(2): 84-95.